




**CellSonic**

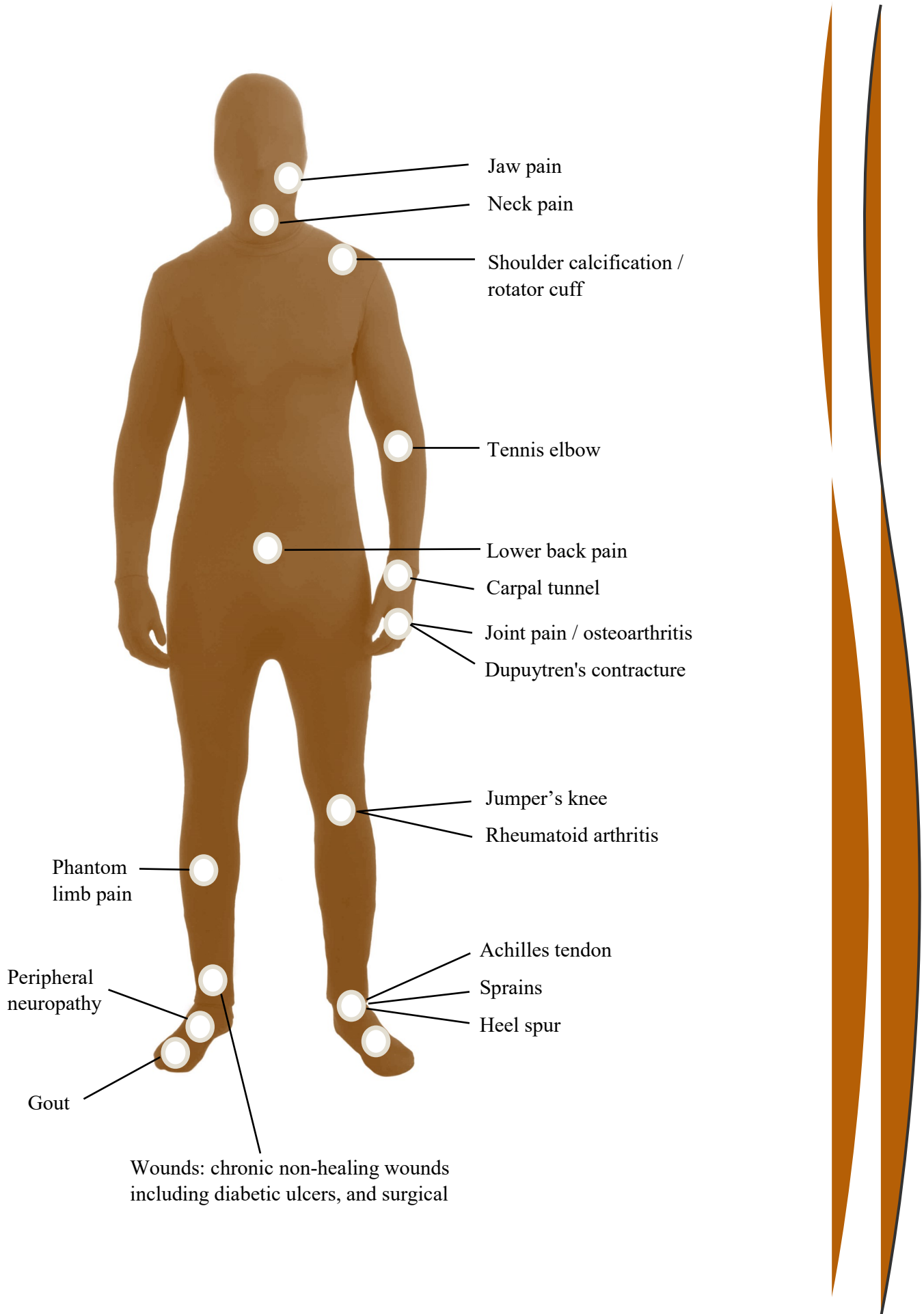
**CellSonic<sup>®</sup> VIPP  
Owner's Manual**





# TABLE OF CONTENTS

	PAGE
Technology Behind CellSonic VIPP .....	5
Types of Shockheads .....	11
Preparation and Treatment Guide .....	13
<hr/>	
<b><i>Treatment of Painful Conditions</i></b>	
Achilles Tendon Irritation/Inflammation .....	15
Carpal Tunnel Syndrome .....	16
Dupuytren's Contracture .....	16
Gout .....	17
Heel Spur—Plantar Fasciitis .....	18
Joint Pain (hands, knees, feet, ankles, hips) .....	19
Joint Pain/Osteoarthritis/Rheumatoid Arthritis .....	19
Jumpers Knee—Patellar Tendonitis .....	20
Lower Back Pain .....	20
Neck Pain .....	21
Osteomyelitis of the Jaw Bones .....	22
Peripheral Neuropathy .....	22
Phantom Limb Pain .....	23
Shoulder Calcification—Calcific Tendinitis .....	23
Shoulder Pain—Rotator Cuff inflammation / Impingement Syndrome .....	24
Sprains .....	25
Tennis Elbow—Chronic Lateral Epicondylitis .....	25
Wounds—Chronic, non-healing .....	26
Wounds—Surgical .....	28
<hr/>	
Treatment Protocol Worksheet .....	29-30
Frequently Asked Questions .....	31
Contradictions .....	33
Warranty .....	34
Medical Literature .....	35-49



# Technology Behind CellSonic VIPP

The basic technology is older than most of the FDA-approved drugs on the market today.

A shockwave is:

- An area of very high pressure moving through the air, earth, or water. It is caused by an explosion, earthquake, or by an object traveling faster than the speed of sound.
- A pressure pulse which our ears perceive as sound.
- A series of strong pressure pulses generated in elastic media such as gasses, liquids, or solid substances by ultrasonic aircraft, explosions, lightning with thunder, or other phenomena that create an extreme change in pressure.

The high mechanical tension and pressure distinguishes shockwaves from other kinds of sound waves, such as ultrasound waves. Additionally, ultrasound produces heat; shockwaves do not produce significant heat in the body.

In 1980, the first patient was treated successfully for kidney stones with a new, minimally invasive method called “extracorporeal shockwave lithotripsy.” Surgery to remove a kidney stone used to be one of the most difficult treatments to perform. The invention of non-invasive lithotripters changed everything; a new era of medicine was born.

Dornier, a German company, created that first “shockwave” medical device to break up kidney stones. The energy pulse breaks the sound barrier, which results in a pressure pulse which we hear as a sound. The event is identical, only on a smaller scale, to the “boom” sound made when a plane is flying faster than the speed of sound.

The effect produced by the lithotripsy machine was called “Stoßwelle” which translated into English as “shockwaves.” That was unfortunate because in English it gives the impression that an electric shock is involved when it is not, and that it is a wave which it is not. It is an acoustic event, a pressure pulse, and each individual event is interpreted by our ears as a bang or a pulse. Nevertheless, “shockwave” became the popular word.

The first lithotripters used the **electrohydraulic** principle. This method was subsequently refined by a joint effort of scientists, engineers, and medical specialists and is now used, in a more sophisticated form, in several types of smaller machines. As the technology evolved, the use of smaller devices went in primarily two directions: to chiropractors and physiotherapists who use ESWT for aches and pains, and to dermatologists and vascular surgeons who use ESWT for wound healing.

Extracorporeal Shockwave Therapy, or ESWT, is a term applied to all non-invasive shockwaves/pressure pulses used for a variety of medical treatments from breaking kidney stones to healing wounds and treating a calcified shoulder. The word “lithotripter” is mostly reserved for the kidney stone machines. Machines that break kidney stones are very powerful and focused at about 140 mm into the kidney. Machines used for wound healing and pain resolution are less powerful and the depth of penetration can be more adjusted.

The term “shockwave machine” is being applied to smaller hand-held machines used for wound healing and pain resolution, and there are different technologies:

### **FOCUSED SHOCKWAVES**

*Electrohydraulic* – High energy pressure is generated by discharging a spark in water, creating acoustic (sound) waves. There is a rapid rise in pressure which is then focused by an elliptical reflector and targeted to the diseased area to produce a therapeutic effect.

*Electromagnetic* – This involves an electric current passing through a coil to produce a strong magnetic field. A lens is used to focus the waves; the therapeutic point is defined by the length of the focus lens.

*Piezoelectric* – Piezoelectricity is the creation of voltage across the sides of a crystal when you subject the crystal to mechanical stress. In ultrasound equipment, a piezoelectric transducer converts electrical energy into extremely rapid mechanical vibrations. These ultrasound vibrations can be used for scanning, cleaning, and all kinds of other things. In therapeutic applications, this involves a large number of piezoelectric crystals in water. The arrangement of the crystals defines the focus.

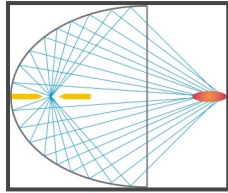
### **UNFOCUSED SHOCKWAVES**

*Radial pressure wave* – This is usually not considered true extracorporeal shockwave therapy, but more of a pressure wave therapy. A “shockwave” is defined as being a generated energy wave that moves faster than the speed of sound (1500 meters per second). Radial pressure waves travel at speeds of approximately 10 meters per second; hence, no actual shockwave is produced. Radial pressure waves are slower, less intense, elongated, and more sinusoidal in appearance. The waves cannot be focused.

Of the four, the **electrohydraulic** method appears to be the most effective therapeutically, likely due to the rapid rise time of the pressure pulse. Also, results are obtained with a smaller number of sessions.

CellSonic VIPP uses the **electrohydraulic** method. These high energy focused shockwaves rise 1000 times faster and have a peak pressure 10 to 100 times greater than radial (unfocused) shockwaves.

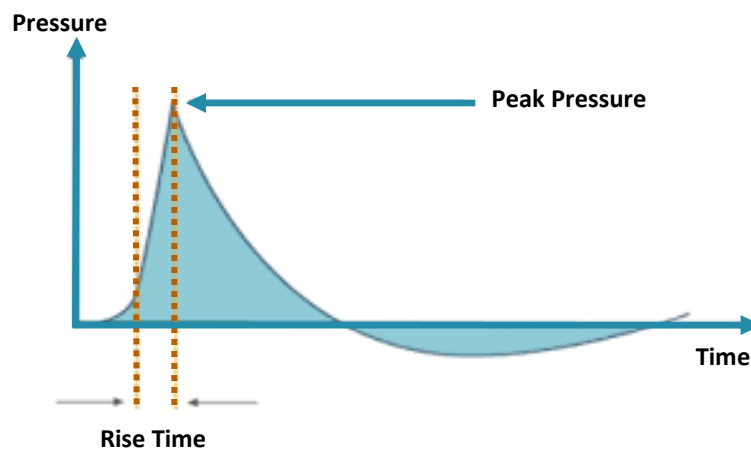
Electrohydraulic pressure pulses have proven effective for treating musculoskeletal conditions below the skin surface (heel spur, calcified shoulder, patellar tip syndrome, non-union fractures, and wounds). Radial unfocused pressure waves have proven to be effective only for conditions near the surface (tennis elbow and achillodynia).



Pressure pulses are generated when voltage jumps between electrodes in a spark plug in an aqueous medium and produces a sonic “bang.” Then the pulses are focused by the parabola in the shockhead to the area being treated.

The essential feature of a most successful pressure pulse is that it has a sudden rise of decibels; the fastest method is achieved by use of a spark plug so voltage jumps a gap in electrodes.

As the technology has evolved, the terminology has yet to catch up. CellSonic VIPP is different in that it generates a *very intense pressure pulse* (VIPP). These intense pulses are generated at a rate of 4 per second. The rise time – the amount of time it takes for the pulse to reach maximum pressure – is faster than other machines on the market.



Decades of observation in the therapeutic arena demonstrate that what matters most is the suddenness of the rise time – the speed at which the pressure has increased when it hits the cell.

Two features make the CellSonic VIPP unique in the field: its fastest rise time, and its generation of an electromagnetic field which is capable of penetrating bone.

As pressure pulses travel through the body, no harm is done to healthy cells; they withstand the pressure and react by signaling the body to initiate a healing response. But it’s a different story when it comes to infectious agents.

Chronic nonhealing wounds, for example, have problematic infectious agents. When treated with CellSonic VIPP, antibiotics are not needed because the pressure pulses kill bacteria, viruses, and fungi.

## How Very Intense Pressure Pulses Help Tissue Regeneration

CellSonic VIPP stimulates the body to regenerate damaged tissues. Recent studies have greatly advanced the understanding of how pressure pulses affect human biology.

Dr. Rainer Mittermayr of the Ludwig Boltzmann Institute for Experimental and Clinical Traumatology, Vienna, Austria, studied ESWT in the 2000s. Mittermayr and his team showed that by a mechanism of mechanotransduction, the high-energy acoustic waves translated into biochemical signals, that could activate various cellular and molecular pathways leading to cell activation. This triggering of the cells generated biological responses including angiogenesis, the recruitment of stem cells to the site of shockwave therapy application, cell proliferation, and differentiation and modulation of the inflammatory response. “These mechanisms give the non-invasive technology of shockwave therapy great potential in a broad range of indications because it activates the body’s own mechanisms,” Mittermayr concluded.<sup>1</sup>

Studies have also shown that ESWT stimulates osteoblasts—bone cells responsible for bone healing and the production of new bone. ESWT also stimulates fibroblasts—cells responsible for the healing of connective tissue such as tendons, ligaments, and fascia.<sup>2,3</sup>

ESWT has been found to more effective than transcutaneous electric nerve stimulation (TENS) therapy for treating chronic calcific tendinitis.<sup>4</sup>

ESWT has emerged as a favorable treatment modality for erectile dysfunction (ED) because it offers the possibility of permanent restoration of erectile function. The stress and microtrauma triggered by ESWT induces biological reactions that result in the release of angiogenic factors that trigger neovascularization of the tissue with subsequent improvement of the blood supply.<sup>5</sup>

---

1. “Shockwave Therapy.” Paper by Nayanah Siva, June 2016, accessed at <http://europe.medtronic.com/xd-en/transforming-healthcare/Eureka/innovation-articles/shockwave-therapy.html>


2. Hausdorf J, Sievers B et al. Stimulation of bone growth factor synthesis in human osteoblasts and fibroblasts after extracorporeal shock wave application. *Archives of orthopaedic and trauma surgery*. 2011;131,303-9

3. Schaden W, Mittermayr et al. Extracorporeal shockwave therapy (ESWT) – First choice treatment of fracture non-unions? *International Journal of Surgery*, Dec 2015, Vol 24, Part B

4. Pan P-J, Chou C-L et al. Extracorporeal shock wave therapy for chronic calcific tendinitis of the shoulders: a functional and sonographic study. *Physical Medicine and Rehabilitation*, July 2003, vol 84, issue 7

5. Peak TC, Kammel K et al. Update on the Treatment of Erectile Dysfunction. *Reference Module in Biomedical Sciences*, 2015





Some patients report that treatment with ESWT provides an analgesic effect immediately after treatment which may last several days.

ESWT reduces pain caused by inflammation and swelling.

The non-invasive technology of ESWT has been used on an ever-increasing number of conditions including:

#### *Orthopedic*

- Low back pain/lumbago
- Achillodynia
- Planter fasciitis (heel spurs)
- Lateral epicondylitis of the elbow
- Calcific tendonitis of the shoulder
- Trochanteric bursitis
- Myofascial trigger points

#### *Dermatology*

- Non-healing wounds
- Chronic diabetic and non-diabetic ulcers
- Psoriasis
- Toe nail fungus
- Scars
- Non-union fractures
- Dupuytren's contracture
- Erectile dysfunction
- Peyronie's disease
- Tendonitis of the iliotibial tract
- Patellar syndrome
- Avascular necrosis of the femoral head

#### *Other*

- Sports injuries
- Bone healing
- Osteonecrosis
- Myocardial ischemia/Ischemic heart disease
- Periodontal disease
- Gout
- Venous/varicose veins
- Kidney stones
- Gall bladder stones
- Salivary gland stones
- Traumatic wounds including burns

“Although some details are still under study, it is known that [ESWTs] are able to relieve pain, as well as to positively regulate inflammation (probably as immunomodulator), to induce neoangiogenesis and stem cells activities, thus improving tissue regeneration and healing.

ESWT can be nowadays considered an effective, safe, versatile, repeatable, noninvasive therapy for the treatment of many musculoskeletal diseases, and for some pathological conditions where regenerative effects are desirable, especially when some other noninvasive/conservative therapies have failed.”

d'Agostino MC, Craig K et al. Shock wave as biological therapeutic tool: From mechanical stimulation to recovery and healing, through mechanotransduction. International Journal of Surgery, Dec 2013

## CellSonic VIPP is sold to medical professionals with the following qualification(s):

- M.D.
- D.O.
- D.C.
- D.P.M.
- D.D.S., D.M.D.
- Naturopaths (ND or NMD)
- Nurse Practitioners
- Physician Assistants
- Veterinarians
- Physical Therapists
- Acupuncturists and Massage Therapists – Those licensed or trained to put hands on people. This may vary upon differences in state laws.

# Shockheads

The shockheads deliver a very intense pressure pulse (VIPP). The pressure pulse is similar in nature to the sonic boom from an airplane going faster than the speed of sound. As you work with the shockheads, you will hear a bang, 4 times a second.

Your ear interprets the pressure pulses as sound: the bang is actually a pressure pulse. The acoustic pulse is focused by a parabola in the shockhead.

The shockhead does not put energy into the body. It creates an intense pressure pulse with what is essentially a spark plug inside the shockhead.

You must shake the shockhead prior to use to make effective pulses. Gasses form in the shockhead from the electricity made by the spark plug inside the shockhead. Shaking the shockhead mixes everything back together and a more effective pulse/louder bang can be heard. So if you are doing a series of 4 treatments at one time, 300 pulses each (perhaps because you are working in several different locations), you would shake the shockhead at the start of each series of 300.

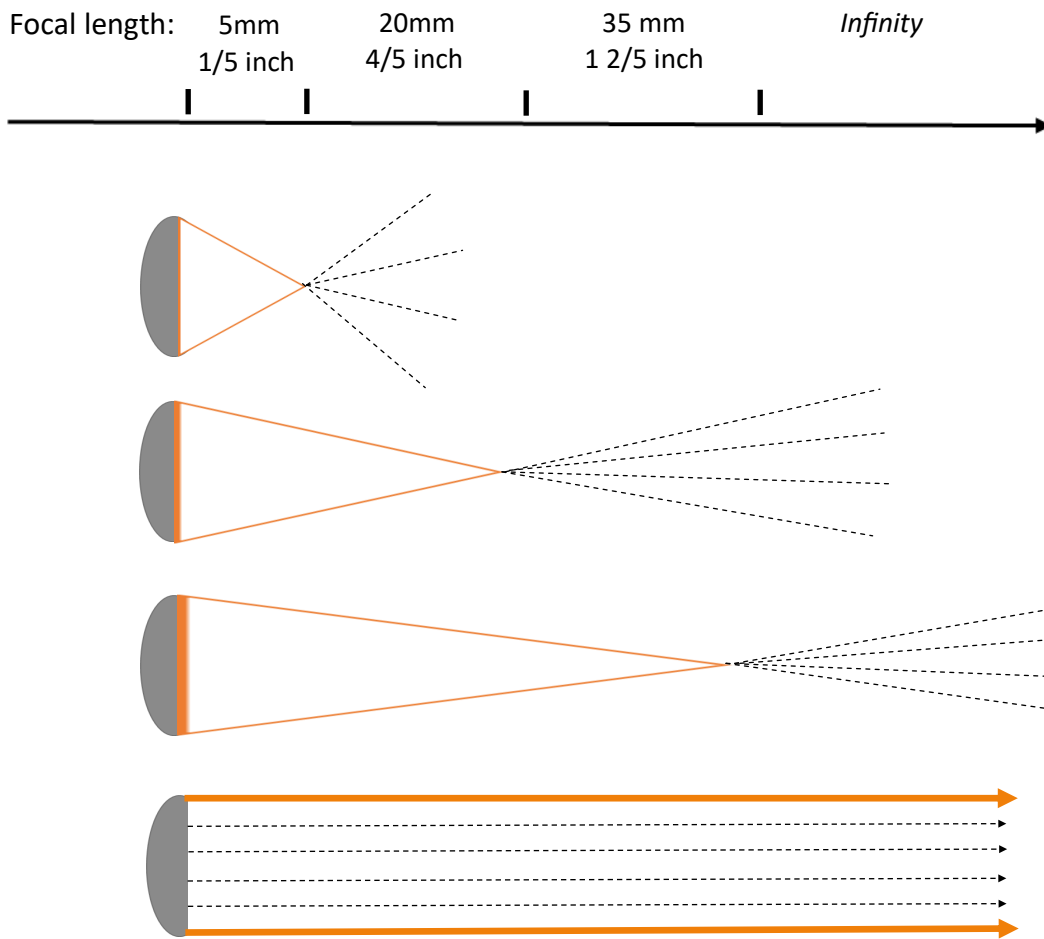
Each shockhead will deliver 50,000 pulses over its lifetime; the spark plug wears out. Keep new, unused shockheads in the refrigerator; they keep fresh for 4 months.

There are 4 different shockheads. The diameter of each shockhead is the same. However, each has a different focal length. The focal point is a point of convergence. Beyond that point, the pulse diverges and disperses its effect over a wider area. Where a dispersed effect is required, a short focal length can be useful. When it is not known exactly where to aim, a scatter is more likely to catch the problem areas or infections.

There is a 5mm, 20mm, 35mm, and infinity head. In the case of the infinity head, there is no focal point; the pulse travels until it hits an object such as bone, or a dense object such as a wall.

Focal Length	Indications
5 mm	Orthopedic and Physical Therapy
20 mm	Orthopedic and Physical Therapy
35 mm	Orthopedic
Infinity	Non-healing wounds, diabetic wounds and ulcers, skin infections

**FOCAL LENGTHS OF DIFFERENT SHOCKHEADS (how far the pressure wave travels to a point where it converges with full force before dispersing its pressure)**



The infinity head is the most popular because it could be used on most every condition.

The 35mm head is popular with those who use CellSonic VIPP on horses.

Many chiropractors and physiotherapists prefer the 20mm head because it spreads the pulses over a wider area. It seems that for physiotherapy, it is less painful on patients.

For problems closer to the skin surface, the 5mm head is often used.

If the patient says, “Ouch!” that is normal. However, if they are exclaiming consistently because of pain, that is too much. Treatment of soft tissues cause no pain. It is when the pulses hit bone that the treatment can be too painful. In this case, turn down the intensity of the machine.

If the patient has a calcification such as calcific tendonitis, you probably want to inject a local anesthetic because the treatment could be painful.

# Preparation and Treatment Guide

It is advised that the operator wear ear plugs or sound-blocking headphones. For treatments close to the face, you may offer the patient ear plugs or headphones.

1. Identify the area to be treated. You may wish to use a washable marker to mark the area which makes it easier to have an overview of all the areas needing treated.
2. Cover the shockhead with cling film (such as Saran™ Wrap) for sanitary purposes. Check that no air bubbles are trapped under the film; pressure pulses do not go through bubbles of air.
3. Pressure pulses travel only through liquid; use ultrasound or other gel liberally on areas to be treated.
4. Select the correct shockhead and shake it vigorously at least 5-6 times prior to use to prepare the shockhead to make the best quality pulses.
5. Set the number of pulses.
6. Set the energy level.
7. Place the shockhead against the area to be treated and press the start button.
8. The shockhead should be moved around the treatment area to change the angle of the wave. This also prevents the echo effect of returning waves.
9. When treatment is completed, remove the cling wrap from the shockhead and dispose of it in a secure bin. Provide patients with a towel to remove the gel from their skin.

The CellSonic VIPP machine is equipped with a foot pedal which you may find makes the on/off feature easier to use.

You can opt to use the “Soft Start” option on the keypad. The machine can be set to start at a lower energy level more tolerable to the patient, and automatically rise to higher energy levels. The analgesic effect numbs the nerves, thus improving the treatment by avoiding anesthetics which are known to reduce the effect of pulses on soft tissue.

This treatment complements ultrasound, friction, and other methodologies a doctor or physiotherapist would look to apply.



# Treatment of Conditions

The following protocols are not meant to be absolutely precise instructions. When you handle the machine, you will get a feel for it. Like medicine, the use of this machine is as much an art as a science. And each patient is unique.

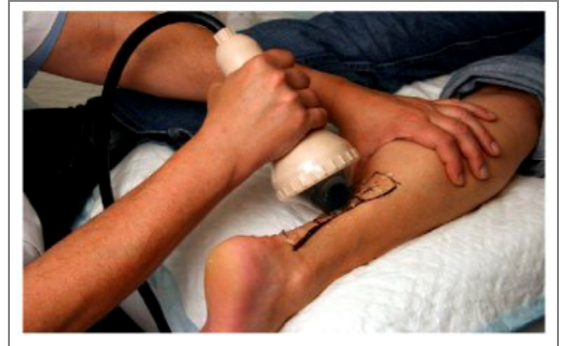We constantly monitor successful techniques used by other doctors and physiotherapists. The protocols described in the following pages are based on results seen in Europe and India. Your results may vary due to differences in diet, lifestyle, environmental exposures, and operator proficiency.

## ACHILLES TENDON IRRITATION/INFLAMMATION

SHOCKHEAD	# OF PULSES	ENERGY LEVEL	INTERVAL BETWEEN TREATMENTS	NUMBER OF TREATMENTS (AVERAGE)
20 mm or Infinity	500 to 1,000	3 to 6	1 month	2-4

Depending upon the regions to be treated, often divided over multiple areas along the tendon, the administered number of shockwaves can be from 500 to 1,000 pulses. The energy setting for each tendon area can vary from low to above midrange. Two treatments, and in certain cases, up to 4 treatments for Achillodynia are not unusual due to the potential scale of the injured area.

In general, a maximum number of pulses will be administered for the very first treatment in the tendon (often in more than one area). For the second and possibly third and fourth treatment, the number of pulses needed per tendon area will decrease as well as the energy setting. The first treatment will stimulate tissue growth and the body will then start to heal itself; subsequent treatments boost the process.



**AFTER THE TREATMENT:** The patient generally experiences a distinct reduction of symptoms several days after the treatment. One of the first reliefs for these patients is the experience of less problems with the so-called “morning stiffness.” After therapy on Achillodynia, it can take a number of weeks before complaint-free status is reached.

**PATIENT INSTRUCTIONS:** For the next 1 to 2 weeks after treatment, the patient should restrict physical activity involving the feet. Minimize walking and repetitive movements. Do not overstrain the tendon the first 4 to 6 weeks.

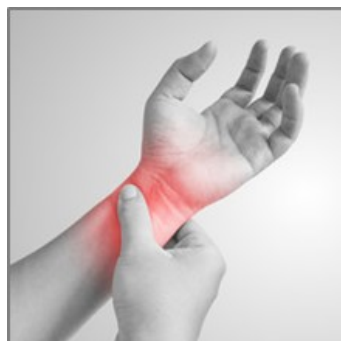## CARPAL TUNNEL SYNDROME

SHOCKHEAD	# OF PULSES	ENERGY LEVEL	INTERVAL BETWEEN TREATMENTS	NUMBER OF TREATMENTS (AVERAGE)
5 mm or Infinity	300	4	3 weeks	2-3

Usually, this is a small area to be treated.

**AFTER THE TREATMENT:** Check for workplace situations that could cause repetitive use injuries. If the carpal tunnel is bi-lateral, check for low thyroid, rheumatoid arthritis, and other medical conditions.

**PATIENT INSTRUCTIONS:** If the problem stemmed from computer use, advise the patient to assess their work environment for correct ergonomic design—the angles involved with the desk and keyboard and chair may be contributing to a repetitive use injury.

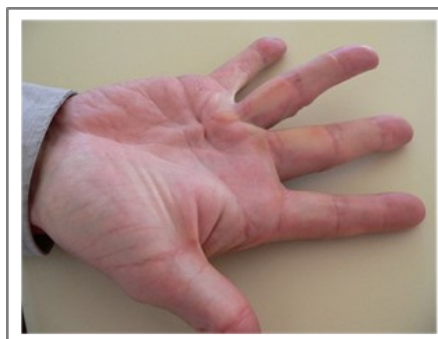

## DUPUYTREN'S CONTRACTURE

SHOCKHEAD	# OF PULSES	ENERGY LEVEL	INTERVAL BETWEEN TREATMENTS	NUMBER OF TREATMENTS (AVERAGE)
5 mm or Infinity	1,000	5	2 weeks	1-2


Aim the shockhead on the area of the palm and the fingers where the tightening is apparent, keeping the shockhead sliding gently around on the gel. If another treatment will help, do it 2 weeks after the first.

**AFTER THE TREATMENT:** Improvements will continue 1 year after the last treatment because the intense pulses are causing new cells to grow thanks to the stem cells called to the site.





Dupuytren's contracture involves similar cell damage to that experienced with plantar fasciitis, Lederhose's disease, and Peyronie's disease. They can all be treated with the same protocol described above except Peyronies which needs fewer pulses at a lower energy level.



The CellSonic VIPP's fast moving sound waves are directed into the palm and fingers. They hit the tightened cord and stretch it. Moreover, they activate stem cells to migrate to the site.

## GOUT

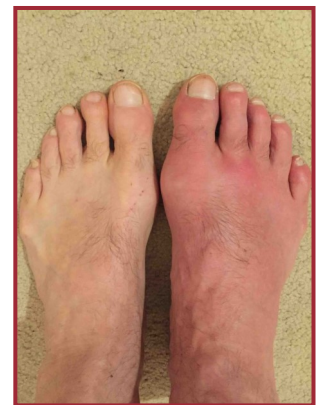SHOCKHEAD	# OF PULSES	ENERGY LEVEL	INTERVAL BETWEEN TREATMENTS	NUMBER OF TREATMENTS (AVERAGE)
5 mm or 20 mm or Infinity	500	4	2 weeks	3

With gout, you are using CellSonic's VIPP to break up crystals, similar to how lithotripsy breaks up kidney stones.

Use the 5mm shockhead in areas that are more superficial; 20mm in areas that are deeper. If a 5mm or 20mm is not available, you can use an infinity shockhead.

**AFTER THE TREATMENT:** Instruct the patient in a diet for the prevention of further gout symptoms.

**PATIENT INSTRUCTIONS:** Pain medication can be continued. Patient can expect the pain to diminish as the particles disintegrate.



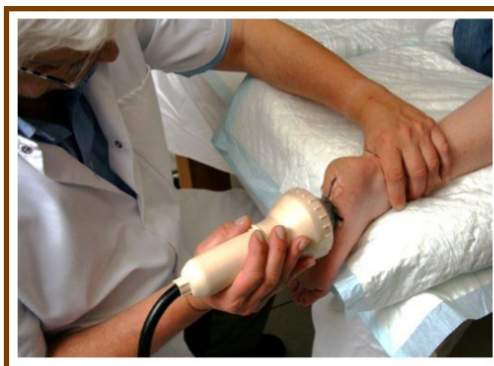## HEEL SPUR—PLANTAR FASCIITIS

SHOCKHEAD	# OF PULSES	ENERGY LEVEL	INTERVAL BETWEEN TREATMENTS	NUMBER OF TREATMENTS (AVERAGE)
20 mm or Infinity	1,200	7	6 weeks in 40% of cases	1 to 2

Use more rather than fewer pulses.

With plantar fasciitis, a second treatment is given after 6 weeks in about 40% of the cases to fully revitalize the degenerative tissue areas. A third treatment is not often needed.


This is the most painful treatment for patients. Use a local anesthetic such as lidocaine or a nerve block when it is too painful.



**AFTER THE FIRST TREATMENT:** The patient should experience, in about a week, less morning stiffness as the first sign of improvement. Complaint-free status comes after 4 to 6 weeks, occasionally longer.

**PATIENT INSTRUCTIONS:** For the first 4-6 weeks after treatment, the patient should walk a little during the day, maybe doing only half of what they were used to and trying to build it up slowly—getting rid of crutches, no cast, maybe soft sport shoes. No walking on bare feet, jumping, standing in one spot for too long, or sports like tennis, etc.

When the heel is hot, cool it with an icepack for 15 to 20 minutes, resting the foot high up on a chair.



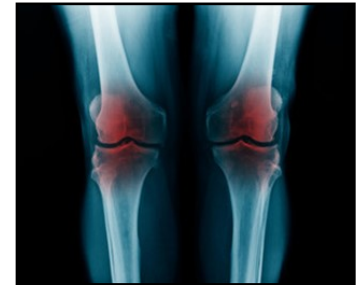Typical sufferers are pregnant women, people who are overweight, waiters, fanatic athletes, those wearing the wrong shoes, e.g., high heels, heavy industrial protective shoes, etc.

Overall results: About 75% of cases are resolved.

## JOINT PAIN (KNEES, HANDS, FEET, ANKLES, HIPS)

SHOCKHEAD	# OF PULSES	ENERGY LEVEL	INTERVAL BETWEEN TREATMENTS	NUMBER OF TREATMENTS (AVERAGE)
20 mm or Infinity	500 - 1,000	4	3 weeks	3 to 6

Knees can be challenging to treat because you will be working within a curved structure. You want to get inside the joint which is made up of concave and convex surfaces. When treating the knee, do not merely aim the shockhead directly into the knee cap (patella). You need to go a bit to the left and to the right to get behind the kneecap. You also want to use the shockhead on the back side of the joint.



During the treatment interval, the body will initiate healing. Depending upon the amount of healing, subsequent treatments may be needed, especially with knees and hips.

## JOINT PAIN/OSTEOARTHRITIS/RHEUMATOID ARTHRITIS

SHOCKHEAD	# OF PULSES	ENERGY LEVEL	INTERVAL BETWEEN TREATMENTS	NUMBER OF TREATMENTS (AVERAGE)
Infinity	Up to 2,000	7	4 weeks	4

On smaller joints, a 5mm or 20mm may be your best choice, although the infinity shockhead can be used on most joints. It depends how intense you want the pulse to be. Bigger joints will require more pulses.

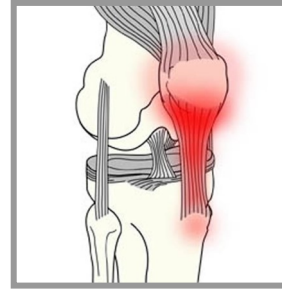
The CellSonic VIPPs will work to break up scar tissue or calcifications that may be in the joint. They will also stimulate both osteoblasts and fibroblasts in the bone. The growth of new cartilage is slow because it has little blood supply.

During the treatment interval, the body will initiate healing. Depending upon the response to healing, subsequent treatments may be needed.


## JUMPERS KNEE—PATELLAR TENDONITIS

SHOCKHEAD	# OF PULSES	ENERGY LEVEL	INTERVAL BETWEEN TREATMENTS	NUMBER OF TREATMENTS (AVERAGE)
20mm or Infinity	1,000	7 with soft start	1 month	3

The 20mm shockhead is preferred. You want to get inside the joint which is made up of concave and convex surfaces. You are working within a curved structure. If doing the knee, you can't just aim into the knee cap. You need to go a bit to the left and the right to get under the kneecap. You want to treat the knee, for example, by also using the shockhead on the back side of the joint.



**PATIENT INSTRUCTIONS:** Advise against further repetitive use as the damage will likely recur.



Jumper's knee is believed to be caused by repetitive stress placed on the patellar or quadriceps tendon during jumping. It is an injury specific to athletes, particularly those participating in jumping sports such as basketball, volleyball, or high or long jumping. Jumper's knee is occasionally found in soccer players, and in rare cases, it may be seen in athletes in non-jumping sports such as weight lifting and cycling.

## LOWER BACK PAIN

SHOCKHEAD	# OF PULSES	ENERGY LEVEL	INTERVAL BETWEEN TREATMENTS	NUMBER OF TREATMENTS (AVERAGE)
Infinity	1,000 to 2,000	4	1 month	2

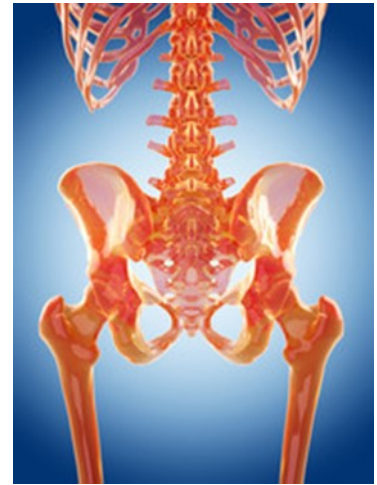
First position the patient. Have the patient sit on a chair or stool with their back toward you and have the patient point to the area of pain. The sacroiliac joint may be the source of pain, or a vertebrae, muscle, or other area. Treat the area where the patient points to the pain.

Consider treating muscle (the source of the pain may be spasms) as well as the spinal column.

CellSonic VIPP will affect nerves and bones.

As you move up and down the spine, also work the shockhead a bit from left and right to angle the delivery of pulses between the vertebrae of the spine. If you also work along the hip, you will want to use a greater number of pulses (2,000).

**PATIENT INSTRUCTIONS:** If the patient does a lot of lifting, that person needs to be instructed how to lift properly. Depending upon the amount of damage done, they may not want to lift continuously on the job anymore. It may be said that healing back pain does not necessarily qualify a person for a continued lifetime of heavy-duty lifting.



## NECK PAIN

SHOCKHEAD	# OF PULSES	ENERGY LEVEL	INTERVAL BETWEEN TREATMENTS	NUMBER OF TREATMENTS (AVERAGE)
20 mm or Infinity	500	4	4 weeks	2 or 3

This is similar to treating back pain but be careful because you are getting close to the brain.

First position the patient on a chair or stool with their back toward you. Identify the area of pain. As you move up and down the spine, also work the shockhead a bit from left and right to angle the delivery of pulses between the vertebrae of the spine.

**PATIENT INSTRUCTIONS:** Instruct the patient on range-of-motion exercises. Some people carry a purse or bag over the shoulder with a strap that puts weight on the shoulder. This behavior needs to be changed/modified so that the injury will not re-occur. Recommend alternating shoulders, or use of a long purse strap that crosses over the bodice, or use of *both* straps of a backpack.


## OSTEOMYELITIS OF THE JAW BONES

SHOCKHEAD	# OF PULSES	ENERGY LEVEL	INTERVAL BETWEEN TREATMENTS	NUMBER OF TREATMENTS (AVERAGE)
5 mm or 20 mm	100 per each tooth area	4	4 weeks	5 or 6

**NOTE:** Only experienced, qualified people should use CellSonic VIPP on the mouth because the pulses could damage the eyes, ears, and brain if not handled carefully.

Fill the side of the mouth to be treated with water to transmit the pulses and treat with about 100 pulses per each tooth area. Make sure the patient is sitting up to minimize the possibility of choking on the water. Some patients may request more pulses at higher energy levels because they are desperate to kill the infection and antibiotics have been ineffective. But you need to counsel patience and explain to them they are in danger of loosening their adjacent teeth.

**AFTER THE TREATMENT:** The situation improves eventually. Pain reduces and bones strengthen but it takes time, a few months.



CellSonic can heal and cure problems in the mouth that are impossible by other means because the VIPP generates a healing electromagnetic pulse that travels through bone.

## PERIPHERAL NEUROPATHY

SHOCKHEAD	# OF PULSES	ENERGY LEVEL	INTERVAL BETWEEN TREATMENTS	NUMBER OF TREATMENTS (AVERAGE)
5 mm or 20 mm or Infinity	500 to 2,000	4	2 weeks	3

Plan to use 500 to 2,000 pulses, depending upon the area being treated. If you are treating just the foot, perhaps just 500 pulses. But if you are also treating up the leg, perhaps 2,000 is more appropriate.

**TRY TO FIND THE CAUSE:** Check for diabetes, low thyroid, B vitamin deficiency—investigate what is the fundamental cause of the neuropathy.

## PHANTOM LIMB PAIN & ASSOCIATED NON-HEALING WOUND

SHOCKHEAD	# OF PULSES	ENERGY LEVEL	INTERVAL BETWEEN TREATMENTS	NUMBER OF TREATMENTS (AVERAGE)
Infinity	1,000	4	2 weeks	1-3

Apply the shockhead to the amputation stump and around the edges of the stump. The successful treatment will retrain the nerves to recognize the missing length of limb.

Ideally, the CellSonic VIPP treatment begins in the hospital. This can negate the need for antibiotics, close the wound fully, and minimize scars.

**AFTER THE TREATMENT:** They can continue to use their prosthesis immediately.

## SHOULDER CALCIFICATION—CALCIFIC TENDINITIS

SHOCKHEAD	# OF PULSES	ENERGY LEVEL	INTERVAL BETWEEN TREATMENTS	NUMBER OF TREATMENTS (AVERAGE)
20 mm or Infinity	1,200	6	6	1 to 3


For treatments close to the face, you may wish to offer the patient ear plugs or noise-blocking headphones.

Locations of the calciferous deposits will be determined by palpation or ultrasound.

**AFTER THE TREATMENT:** The patient should not wear a sling or cast. The patient has to stay in motion with his/her treated arm-shoulder from day one.

**PATIENT INSTRUCTIONS:** The patient should be instructed in gentle range of motion exercises and continue them for 4 to 6 weeks. No lifting of heavy items, including children etc., and definitely not with the arm above shoulder height. Avoid resting the arm/elbow on arm rests, such as in a car. Never try to lift one's body out of a chair by pressing the elbow towards the armrest of the seat when getting up.

The more the still swollen tendon is pressed against the shoulder bone, the more painful it will be. Trying to let the arm hang loose alongside the body is best. Avoid repetitive movements for too long. Try to vary the movements or stop when the shoulder starts hurting again.




Improvement will occur after 1 week. To be complaint-free takes 4 to 6 weeks at least. There are good results in about 75% of the cases, with 1 or 2 treatments depending on the number of calciferous deposits scattered in the supraspinatus. Intervals between treatments are preferably 6 weeks. A third treatment for calcified shoulder is quite rare.

### SHOULDER PAIN (ROTATOR CUFF INFLAMMATION — IMPINGEMENT SYNDROME)

SHOCKHEAD	# OF PULSES	ENERGY LEVEL	INTERVAL BETWEEN TREATMENTS	NUMBER OF TREATMENTS (AVERAGE)
20 mm or Infinity	1,200	6	6	1 to 3

For treatments close to the face, you may wish to offer the patient ear plugs or noise-blocking headphones.

**PATIENT INSTRUCTIONS:** Instruct the patient in gentle range-of-motion exercises.



Shoulder impingement syndrome, also called subacromial impingement, painful arc syndrome, supraspinatus syndrome, swimmer's shoulder, and thrower's shoulder, is a clinical syndrome which occurs when the tendons of the rotator cuff muscles become irritated and inflamed as they pass through the subacromial space, the passage beneath the acromion. This can result in pain, weakness and loss of movement at the shoulder. Rotator cuff injuries occur most often in people who repeatedly perform overhead motions in their jobs or sports. Examples include painters, carpenters, and people who play baseball or tennis. The risk of rotator cuff injury also increases with age.

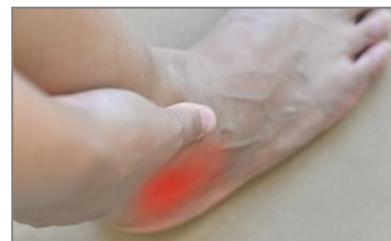

## SPRAINS

SHOCKHEAD	# OF PULSES	ENERGY LEVEL	INTERVAL BETWEEN TREATMENTS	NUMBER OF TREATMENTS (AVERAGE)
20 mm or Infinity	500	4	2 weeks	2

The shockhead is addressing the injury to a muscle or tendon. The pulses will prompt the body to speed healing in those area.

If it is an old injury, CellSonic gives the body a second chance to heal in this area.



**PATIENT INSTRUCTIONS:** CellSonic delivers an analgesic effect for about 2 days so patients should be advised not to “over do it” since they will not feel the full force of the pain.

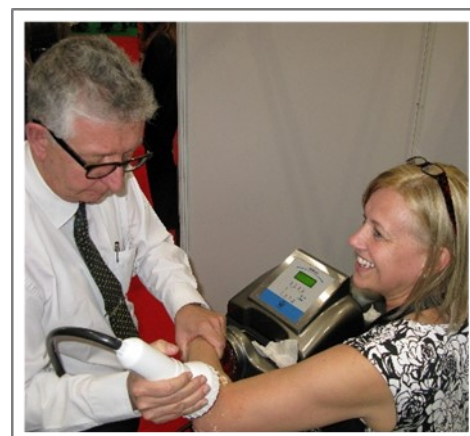## TENNIS ELBOW — CHRONIC LATERAL EPICONDYLITIS

SHOCKHEAD	# OF PULSES	ENERGY LEVEL	INTERVAL BETWEEN TREATMENTS	NUMBER OF TREATMENTS (AVERAGE)
5 mm or 20 mm	1,000	4	4-6 weeks	1-2

The 5mm head is preferred because this is a superficially located condition. Inject a local anesthetic.


Some patients note improvement with less pain after about a week. To become complaint-free takes at least 4 to 6 weeks, perhaps more. About 70% of patients report no more pain after 1 treatment. There may be a second treatment after 6 weeks for some patients.

**PATIENT INSTRUCTIONS:** It is important that the patient keeps using the arm without a sling or a cast. The patient should be instructed in range of motion exercises. Use the elbow and arm in a sensible way so that it is self-improving and developing vascularization.



Do not overstrain it or carry heavy things in the first 4 to 6 weeks. Depending on the sort of work the patient does, one could slowly get back to normal, as before the tennis elbow pain, after 1 to 2 weeks.

Be careful to avoid too many repetitive movements such as suffered by computer-mouse operators, supermarket cashiers, plumbers, carpenters, truck drivers, painters wielding a brush, nurses helping patients in and out of bed, and housekeeping jobs such as vacuum cleaning, dishwashing, window cleaning, etc. Change the type of continuous movement often.



Overall results suggest a total resolution for more than 70% of patients.

### WOUNDS—CHRONIC, NON-HEALING

SHOCKHEAD	# OF PULSES	ENERGY LEVEL	INTERVAL BETWEEN TREATMENTS	NUMBER OF TREATMENTS (AVERAGE)
Infinity	100 per sq cm plus another 200 around the wound	4	1-3 days; treat when you change dressings	1-6

This applies to all types of wounds, including burns, diabetic foot, chronic leg ulcers.

You treat the wound when you change the dressing, which may be 3 times a week.

Continue to treat the wound until you see closure—some close quickly, others more slowly.

Clean the wound thoroughly. Old, flaky pieces of skin must be removed. Apply a non-bubbly, anti-infective agent such as Octenisept® that can be left in the wound after treatment. Over this, lay a sheet of cling wrap (such as Saran™ Wrap) to act as a germ barrier. Atop the cling wrap, spread the ultrasound gel to carry the pressure waves.

Apply 100 pulses for every square centimeter of wound and the area around it to kill infections lurking below. It is very important to treat *around* the wound as well as the wound itself. This immediately kills infection and increases blood flow.

**AFTER THE TREATMENT:** Remove the cling wrap and dispose of as a contaminated item. Remove as much ointment as possible from the wound and dress the wound appropriately. Clean the shockhead thoroughly as usual.

**PATIENT INSTRUCTIONS:** Continue with proper wound care.

**FROM THE ACADEMIC LITERATURE:** The use of CellSonic VIPP for wound healing was spearheaded by Dr. Christian Busch at Tübingen University in Germany. His clinical findings include that nerve repair is evident in wound healing—nerves have grown in the new skin—and the new skin is almost without scars.

According to Dr. Christian Busch:


Our standard weekly/biweekly routine ulcer treatment algorithm (e.g, for venous leg ulcers or diabetic foot ulcers) is as follows: 1. cleansing/disinfection of the wound with Octenisept® for 3 min, 2. application of ESWT (CellSonic®) onto the entire wound surface and edges, 3. surgical débridement using a ring curette (which is much easier to perform after ESWT), 4. measurement and photo-documentation of the wound, 5. application of a wound dressing (e.g. Mepilex®, Allevyn®, Aquacel®, Sorbact Gel®), 6. compression, if indicated, using the Rosidal® TCS System or two-layered ulcer compression stockings. If necessary, additional advanced therapies are applied (e.g. Apligraf®, PICO®).

— Busch C, Aschermann I, Mnich Ch.D. Treatment of chronic ulcers-A critical short analysis, *Phlebologie*, January 2017

In that 2017 study, CellSonic VIPP was used on chronic wounds—venous and arterial ulcers. More than 90% showed a positive response, with 41% showing complete healing. The use of CellSonic VIPP was found to:

- Influence the cellular morphology of human fibroblasts, keratinocytes and dermal microvascular endothelial cells.
- Activate cell migration in fibroblasts and keratinocytes.
- Induce expression of cell cycle regulatory genes and proteins.
- Alter the expression of cytoskeletal proteins in fibroblasts.
- Activate immune response factors in human keratinocytes.

See page 49 for more detail of this study. All the patients who participated in this study had been scheduled for amputation and were sent to Dr. Busch “as a last resort.”



**Note:** Infection and lack of vascularization are the primary reasons wounds would refuse to heal. With CellSonic VIPP, the pressure pulse produces a controlled injury in the area which prompts a biological/biochemical response necessary to initiate tissue healing. Complete healing, including the restoration of healthy tissue; the revival of new tissue as replacement for severely crushed scar tissue; growth of new capillaries; regulating vascularization; and strengthening of tendons, muscles, and ligaments etc., takes at least 6 to 8 weeks.

## WOUNDS—SURGICAL

SHOCKHEAD	# OF PULSES	ENERGY LEVEL	INTERVAL BETWEEN TREATMENTS	NUMBER OF TREATMENTS (AVERAGE)
Infinity	100 per sq cm plus another 200 around the wound	4	1-3 days; treat when you change dressings	1-6


The object of using CellSonic VIPP with surgical wounds is to:

- improve wound healing
- minimize scarring
- prevent infections


Do a CellSonic treatment over the stitches and around. Apply 100 pulses for every square centimeter of wound and the area around it to kill infections lurking below. It is very important to treat around the wound as well as the wound itself. This immediately kills infection and increases blood flow.

It should not be necessary to use an antibiotic because the pressure pulses kill bacteria, viruses, and fungi.

**AFTER THE TREATMENT:** Remove the cling wrap and dispose of as a contaminated item. Remove as much ointment as possible from the wound and dress the wound appropriately. Clean the shockhead thoroughly as usual.



Treat all wounds as internal wounds. Healing happens from inside. The pressure pulses cause microscopically interstitial and extracellular responses leading to tissue regeneration.



PATIENT TREATMENT PROTOCOL WORKSHEET

CELLSONIC TREATMENT PROTOCOL (patient name):

DATE	SESSION #	LOCATION, SIZE OF SHOCKHEAD, NUMBER OF PULSES, ENERGY LEVEL									
	1	Left shoulder Infinity 1200 / 6									

Notes:

## FAQs

Q – *What about patients with metal inserts to support bone?*

A – Small items such as stents will reflect the pulses, but most pulses, being an inch in diameter, will blast over it. Pulses that bounce off metal will be deflected—they could bounce sideways at an angle, for example—so consider what that impact may be.

Q – *What about treating anything on the chest wall; is that a problem with the lungs?*

A – Treating the lungs is now commonly done in India. Proceed cautiously on the left side near the heart, only 50 pulses at a time with a break of a few minutes to allow heart rhythm to stabilize if it has been disturbed.

Q – *What about using this therapy after a local anesthetic?*

A – Although CellSonic VIPP is a totally non-invasive procedure, the anesthetic is not. The usual anesthetic is lidocaine given by injection and maybe a series of injections around the area to be treated. This leaves the skin punctured. All medical practice now works on the basis that blood is contaminated until proven otherwise so do as follows:

- After use, the needle must be disposed of properly as medical waste.
- Cover the shockhead with cling wrap. There might be no seepage of blood from the fine injection holes but nevertheless prevention is sensible and a courtesy to your patient. Not only must you avoid cross infection, but the shockhead must not be contaminated and the patient should see that nothing can cross from the shockhead to them.

Q – *How does the CellSonic VIPP kill infectious agents?*

A – The CellSonic pulses kill all infectious agents in their path. The pressure pulse travels faster than the speed of sound through the body. Healthy cells are not affected. Unhealthy cells and bacteria are quickly killed. Note: The body harbors both good and bad bacteria. Therefore, the CellSonic must be applied sensibly. Normally, pulses are directed to a small area of the body at any one time so the concern is minimal. When treating an area in the abdomen, you may wish to incorporate probiotics.

In addition to killing infections, CellSonic VIPP sends stem cells of the right type, in the right quantity, to the right place. Getting the body to initiate the repair mechanism is the best medicine.

*Q – How does this machine differ from other “shockwave” machines?*

A – Electromagnetic, piezoelectric, and radial devices do not create an electromagnetic field and its absence could explain why these machines have a poor performance compared to CellSonic VIPP, especially on wounds. We believe that the short duration of the pulse and the electromagnetic field is what causes the healing reaction in the body. The results speak for themselves. Exactly how it works will be investigated by scientists for years to come.

Decades of observation demonstrate that what is also important is the suddenness of the rise time — the speed with which the pressure has increased by the time it hits the cells. It appears that the very rapid rise time is also what makes CellSonic VIPP a more effective device.

Because CellSonic VIPP is an electrohydraulic device, it can go deeper into the tissues than an electromagnetic, piezoelectric, or radial device.

MANUFACTURER	TECHNOLOGY
CellSonic VIPP	Electrohydraulic
Storz	Electromagnetic
R. Wolf	Piezoelectric
Dornier	Electromagnetic

*Q – Why do I have to keep replacing the shockheads?*

A – Because the spark plug wears out after 50,000 shocks. This is the most effective technology available and we feel the effectiveness is more important than saving a few dollars on less effective technologies. Generally, the CellSonic VIPP requires fewer treatments than other machines. What you are able to accomplish with patients will be a positive marketing tool for your practice.



# Contraindications

CellSonic VIPP should not be used:

- In the case of pregnancy.
- Directly over implanted mechanical devices such as pacemakers, analgesic pumps, and other electrical medical devices.
- Patients who have hemophilia.

Be aware that patients on blood thinners would likely have bruising.

Use extreme caution when treating areas near the head to avoid damage to eyes and the delicate bones of the ears.

When in doubt, ask.

# Warranty

CellSonic VIPP is guaranteed for 2 years against manufacturer's defect. For 2 years from date of purchase, under normal use and care, CellSonic Limited will replace the unit free of charge, if it is found to be defective in material or workmanship.

The shockheads have a shelf life of 4 months beyond which they have no warranty.

CellSonic VIPP traces its origins back to the early Dornier machines and the first lithotripter in Britain at St. Thomas' Hospital in London. CellSonic's founder, Andrew Hague, saw the need for a smaller, more versatile electrohydraulic machine and brought the CellSonic to market in 2010. The company, CellSonic Limited, subsequently developed other machines for other medical applications. CellSonic VIPP is engineered in England. Development and production is licensed to Apex Meditech in India.

Everything CE marked

ISO 13485:2016 and

ISO 9001:2017

Certificate – Сертификат – 證明書 – Certificat – 증명서 – شهادة

**Certificate of Compliance**

No. EC.1282.2P150313.AMU023

**Certificate's Holder:** Apex Meditech  
"Siddhivinayak", Maheshwari Soc., Sahakar Nagar  
No.2, Pune - 411 009, India.

**Certification Safety Mark:**

**Product:** Non-Invasive Therapy System  
Insufflators  
Intra Corporeal Pneumatic Lithotripsy System  
Combination Treatment System  
Wave Therapy System  
(see the following annex I)

**Model(s):**

**Verification to:** Standard:  
EN ISO 14971:2012, EN 60601-1:2006/AC:2010,  
EN 60601-1-2:2007/AC:2010, EN 60601-1-6:2010,  
EN 9802:2008, ISO 15229-4:2012, EN 1041:2005,  
EN 60601-1-8:2007/AC:2010, IEC 60601-2-10:Ed.2  
related to Directive(s):  
93/42/EEC as amended by 2007/47/EC (Medical  
Devices) CLASS II(A, RULE 9 & RULE 11)

Remark: the product(s) has been verified on a voluntary basis; the product(s) satisfies the requirements of the Safety Compliance Mark of ECM, in reference to the above (ISO) standard(s). The above certification mark can be affixed on the product(s) accordingly to the ECM regulation about its release and its use. Regulation can be found at [www.entecma.it](http://www.entecma.it).  
Whereas the Manufacturer is responsible of the CE certification of the product(s) and not exempted to perform all the necessary activities before placing the product(s) on the market.  
The Manufacturer is also responsible to maintain efficient the internal production control to ensure the product(s) are in compliance with the safety compliance mark.  
This certificate can be checked for validity at [www.entecma.it](http://www.entecma.it).

Date of Issue 13 March 2015 Expiry date 12 March 2020

Chief Manager Deputy Manager

Ente Certificazione Macchine Srl  
Via Ca' Bella, 243 - Loc. Castello di Senavalle - 40053 Valsamoggia (BO) - ITALY  
☎ +39 051 4705141 ☎ +39 051 4705156 ✉ info@entecma.it 🌐 www.entecma.it

Certificate – Сертификат – 證明書 – Certificat – 증명서 – شهادة

**Annex I**

No. EC.1282.2P150313.AMU023

**Model(s):** **NON-INVASIVE THERAPY SYSTEM**  
CellSploder-A, CellSploder-B

**INSUFFLATORS**  
digiCARR-4.3, digiCARR-4.2, digiAR-4, CellSufflator VX,  
CellSufflator AX, CellSufflator XT

**INTRA-CORPOREAL PNEUMATIC LITHOTRIPSY SYSTEM**  
LITHOSPLIT 4.1 Digital, LITHOSPLIT 4 Classic, DCM 500

**COMBINATION TREATMENT SYSTEM (SYNCHROWAVE TREATMENT SYSTEM)**  
SynchroWave XL, SynchroWave XT, SynchroWave R,  
SynchroWave T, Time Machine

**WAVE THERAPY SYSTEM**  
CellSonic-A, Sonic-A, CellSonic-B, Sonic-B, CellSonic-C, Sonic-C,  
CellSonic-D, Sonic-D, C-WAVE+, CellSonic Shape CRT,  
Shape CRT, CellSonic Shape VT, Shape RT, CellSonic Shape R,  
Shape R

Ente Certificazione Macchine Srl  
Via Ca' Bella, 243 - Loc. Castello di Senavalle - 40053 Valsamoggia (BO) - ITALY  
☎ +39 051 4705141 ☎ +39 051 4705156 ✉ info@entecma.it 🌐 www.entecma.it

<https://josr-online.biomedcentral.com/articles/10.1186/1749-799X-7-11>

## Extracorporeal shockwave therapy in musculoskeletal disorders

Ching-Jen Wang [Email author](#)

*Journal of Orthopaedic Surgery and Research* 2012 **7**:11 / <https://doi.org/10.1186/1749-799X-7-11>

© Wang; licensee BioMed Central Ltd. 2012

Extracorporeal shockwave therapy (ESWT) began with an incidental observation of osteoblastic response pattern during animal studies in the mid-1980 that generated an interest in the application of ESWT to musculoskeletal disorders. In the past 10 to 15 years, shockwave therapy had emerged as the leading choice in the treatment of many orthopedic disorders including proximal plantar fasciitis of the heel [[1](#), [2](#), [3](#), [4](#), [5](#), [6](#)], lateral epicondylitis of the elbow [[7](#), [8](#), [9](#), [10](#)], calcific tendinitis of the shoulder [[11](#), [12](#)] and non-union of long bone fracture [[13](#), [14](#), [15](#)]. More recently, the use of ESWT had expanded to the treatment of patellar tendinopathy (jumper's knee) and Achilles tendinopathy [[16](#), [17](#), [18](#), [19](#)], and avascular necrosis of the femoral head [[20](#), [21](#), [22](#)]. ESWT has gained significant acceptance from Europe (Germany, Austria, Italy and others) to South America (Brazil, Columbia, Argentina and others), Asia (Korea, Malaysia, Taiwan and others) and North America (Canada and USA), and this had led to the change of European Society for Musculoskeletal Shockwave Therapy to International Society for Musculoskeletal Shockwave Therapy (ISMST) in 2000. In USA, FDA (Food and Drug Administration) first approved the specific shockwave device, OssaTron (High Medical Technology, Lengwil, Switzerland, now Sanuwave/Alpharetta, GA) for the treatment of proximal plantar fasciitis in 2000 and lateral epicondylitis of the elbow in 2003. FDA also approved Epos (Dornier Medical System, Kennesaw, GA) for the treatment of plantar fasciitis and Sonocur (Siemens Medical Systems, Iselin, NJ) for the treatment of lateral epicondylitis of the elbow in 2002, Orthospec (Medispec, Germantown, MD) and Orbasone (Orthometrix, White Plains, NY) for the treatment of plantar fasciitis in 2005. In the meantime, many off-label uses of ESWT were also studied including calcific tendinitis of the shoulder, patellar tendinopathy, Achilles tendinopathy, and non-union of long bone fracture, avascular necrosis of the femoral head and others. The vast majority of the published papers including randomized control trials and cohort studies showed positive effects and evidence base medicine in favor of ESWT [[1](#), [2](#), [3](#), [4](#), [5](#), [6](#), [8](#), [9](#), [10](#), [11](#), [12](#), [23](#)]. However, a few studies reported that ESWT is ineffective or less effective with the results comparable to the placebo effect [[7](#), [24](#), [25](#)], and this has stirred up the debate and controversy. This article reviews the current status of ESWT in the treatment of musculoskeletal disorders.

## Principal of Shockwave Generation

There are three main techniques through which shockwaves are generated. These are electrohydraulic, electromagnetic, and piezoelectric principles, and each of which represents a different technique of generating shockwaves. Electrohydraulic principle represents the first generation of orthopedic shockwave machine. Electrohydraulic shockwaves are high-energy acoustic waves generated by the underwater explosion with high-voltage electrode spark discharge, and the acoustic waves are then focused with an elliptical reflector and targeted at the diseased area to produce therapeutic effect [26]. It is characterized by large axial diameters of the focal volume and high total energy within that volume [27]. Shockwave generation through the electromagnetic technique involves the electric current passing through a coil to produce a strong magnetic field. A lens is used to focus the waves, with the focal therapeutic point being defined by the length of the focus lens. The amplitude of the focused waves increases by non-linearity when the acoustic wave propagates toward the focal point [26, 27]. Shockwave of piezoelectric technique involves a large number (usually > 1,000) of piezocrystals mounted in a sphere and receives a rapid electrical discharge that induces a pressure pulse in the surrounding water steepening to a shockwave. The arrangements of the crystals cause self-focusing of the waves toward the target center, and lead to an extremely precise focusing and high-energy within a defined focal volume. When comparing different shockwave devices, the important parameters include pressure distribution, energy density and the total energy at the second focal point in addition to the principle of shockwave generation of each device.

Shockwave pattern differs from ultrasound wave that is typically biphasic and has a peak pressure of 0.5 bar. Shockwave pattern is uni-phasic with the peak pressure as high as 500 bars [26]. In essence, the peak pressure of shockwave is approximately 1,000 times that of ultrasound wave. There are two basic effects of shockwave. The primary effect is the direct mechanical forces that result in the maximal beneficial pulse energy concentrated at the target point where treatment is provided; and the secondary effect is the indirect mechanical forces by cavitation which may cause negative effect or damage to the tissues [26, 27, 28, 29, 30].


## Mechanism of Shockwave Therapy

The mechanism of shockwave therapy is not fully understood. The most important physical parameters of shockwave therapy for the treatment of orthopedic disorders include the pressure distribution, energy flux density and the total acoustic energy. In contrast to lithotripsy in which shockwaves disintegrate renal stones, orthopedic shockwaves are not being used to disintegrate tissue, but rather to microscopically cause interstitial and extracellular responses leading to tissue regeneration [26, 27].

## Animal Experiments

### Shockwave therapy for bone healing

Several studies had investigated the effects of shockwave therapy on fracture healing and articular cartilage in animal experiments. Haupt et al in an experimental model in rats, confirmed a positive effect of shockwave treatment on fracture healing [31]. Johannes et al showed the promotion of bony union with shockwave therapy in hypertrophic non-



unions in dogs [32]. Wang et al demonstrated that shock wave therapy enhanced callus formation and induced cortical bone formation in acute fractures in dogs and the effect of shockwave therapy appeared to be time-dependent [33]. Forriol et al, however, reached an alternative conclusion and thought that shockwave treatment might delay bone healing [34]. The conflicting results are due different types of animals and different shockwave dosages used. Wang et al had demonstrated that high-energy shockwave therapy produces a significantly higher bone mass including BMD (bone mineral density), callus size, ash and calcium contents, and better bone strength than the control group after fractures of the femurs in rabbits. The effects of low-energy shockwave therapy were less prevailing with comparable results as compared to the control. Therefore, the effect of shockwave therapy on bone mass and bone strength appeared to be dose- and time-dependent [35]. Many other studies also investigated the effect of shockwave therapy on bone healing in animals. The important findings included superoxide mediates shockwave induction of ERK-dependent osteogenic transcription factor (CBFA-1) and mesenchymal cells differentiation toward osteoprogenitors [36]. Extracorporeal shockwave promotes bone marrow stromal cell growth and differentiation toward osteo-progenitors associated with TGF- $\beta$ 1 and VEGF induction [37]. Physical shockwave mediates membrane hyperpolarization and Ras activation for osteogenesis in human bone marrow stromal cells [38], Shockwave promotes bone regeneration by the recruitment of mesenchymal stem cells and expressions of TGF- $\beta$ 1 and VEGF [39].

## Shockwave therapy for insertional tendinopathy

Many studies investigated the effect of shockwave therapy on insertional tendinopathies. Rompe et al demonstrated dose-related effects of shockwave on rabbit tendo Achilles, and suggested that energy flux density of more than  $0.28 \text{ mJ/mm}^2$  should not be used clinically in the treatment of tendon disorders [40]. In their study, a statistically significant increase of capillary formation was noted with higher energy shock wave ( $0.60 \text{ mJ/mm}^2$ ), which also caused more tissue reaction and potential damage to the tendon tissue. Wang et al had demonstrated that shockwaves enhance neovascularization with formation of new capillary and muscularized vessels at the tendon-bone junction of the Achilles tendons in dogs [41]. In another study in rabbit model, Wang et al further demonstrated that shockwave therapy induces the ingrowth of neo-vessels (neovascularization) including capillary and muscularized vessels than the control at the tendon-bone junction. Shockwave therapy releases angiogenetic growth and proliferating factors including *e* NOS, VEGF, and PCNA [42]. The *e* NOS and VEGF began to rise in as early as one week and remained high for 8 weeks, then declined to baseline in 12 weeks; whereas the increase of PCNA and neo-vessels began in 1 weeks and persisted for 12 weeks and longer. Therefore, the mechanism of shockwave therapy may have involved the improvement in angiogenetic growth factors, which in turn induce neovascularization and improve blood supply at the tendon-bone junction of the Achilles tendon in rabbits.

Chronic tendinopathy is an overuse syndrome manifested with pain and tenderness due to mucoid and chondroid degeneration and formation of plump tenocytes and increased fibroblastic and myofibroblastic cells and absent inflammatory cells [43]. Some studies reported that chronic painful tendinopathy exhibited increased occurrence of sprouting nonvascular sensory, substance P-positive nerve fibers and decreased occurrence of vascular sympathetic nerve fibers, and suggested that the altered sensory-sympathetic innervation may play a role in the pathogenesis of tendinopathy [44].

It is believed that shockwave therapy alleviates pain due to insertional tendinopathy by the induction of neovascularization and improvement of blood supply to the tissue, and initiating repairs of the chronically inflamed tissues by tissue regeneration.

## Clinical applications

### Proximal plantar fasciitis

Many studies investigated the effect of shockwave therapy in the treatment of proximal plantar fasciitis and reported a success rate ranging from 34% to 88% [1, 45, 46, 47, 48, 49, 50, 51, 52, 53, 54, 55, 56, 57, 58, 59, 60, 61, 62]. The majority of the published papers reported a positive and beneficial effect of ESWT in proximal plantar fasciitis. Rompe et al suggested that three weekly treatments with 1,000 impulses of low-energy shockwave at 0.06 mJ/mm<sup>2</sup> appear to be an effective therapy for plantar fasciitis with significant alleviation of pain and improvement in function [58]. Wang et al treated 79 patients (85 heels) with plantar fasciitis including 59 women and 20 men with an average age of 47 years (range 15-75 years) with shockwave therapy. At one-year follow-up, the overall results were 75.3% complaint free, 18.8% significantly better, 5.9% slightly better and none unchanged or worse. The recurrent rate was 5% [60]. It was concluded that shockwave therapy is a safe and effective modality in the treatment of proximal plantar fasciitis.

In contrast, few studies reported the opposite results of ESWT in the treatment of plantar fasciitis [7, 24, 25, 63, 64]. Buchbinder R et al compared 81 patients who received ultrasound-guided ESWT given weekly for 3 weeks to a total dose of at least 1,000 mJ/mm<sup>2</sup> with 85 patients in the placebo group who received treatment to a total dose of 6.0 mJ/mm<sup>2</sup>, and concluded that no evidence to support a beneficial effect of ESWT over placebo on pain, function and quality of life [24]. Haake M et al compared 135 patients allocated to ESWT with 137 patients allocated to placebo and the results showed that ESWT is ineffective in the treatment of chronic plantar fasciitis [64]. In a randomised double blind control trial, Speed CA et al concluded that no treatment effect of moderate dose of ESWT in subjects with plantar fasciitis. Efficacy may be highly dependent upon machine types and treatment protocol [25]. Therefore, controversy exists on the effect of ESWT in the treatment of chronic plantar fasciitis. The differences are probably due to the difference in methodology of the study, the patient selection criteria, the use of different devices, different energy levels and the total energy and the outcome measurements.

Several studies compared the effect of ESWT with surgery, local corticosteroid injection or physical therapy in the treatment of proximal plantar fasciitis [62, 65, 66]. Surgical treatment by plantar fasciotomy and ESWT showed comparable functional outcomes, however, ESWT incurred no surgical risks including surgical pain [62]. Physical therapy has shown to be comparable or better effect than ESWT in proximal plantar fasciitis, however, physical therapy is time consuming and inconvenient [63]. Corticosteroid injection shows better short-term effect, but the long-term results favor ESWT [66].

The application of ESWT in proximal plantar fasciitis is performed with either local anesthesia or no anesthesia. Several reports showed that ESWT is less effective when the treatment is performed with the use of local anesthesia [67, 68]. The majority of our patients were treated with no local anesthesia. However, our observations failed to distinguish any difference between treatment with or without local anesthesia. In case patient is unable to tolerate the procedure because of pain during treatment, the anesthesia with constant sedation can be used.

The complications of ESWT in proximal plantar fasciitis are low and negligible. Local reddening, ecchymosis, or mild hematoma, and migraine are among the list of complications. The complications can be successfully managed conservatively and spontaneous recovery is anticipated.

In summary, the literature review unveiled discrepancy and controversy on the effect of ESWT on proximal plantar fasciitis. Many factors can influence the effects of ESWT in the treatment of proximal plantar fasciitis. The vast majority of the published papers are in favor of ESWT. Additional studies are needed to validate the effectiveness of ESWT in the treatment of proximal plantar fasciitis.

## Lateral epicondylitis of the elbow

Several studies investigated the effect of shockwave therapy in patients with lateral epicondylitis of the elbow, and the success rate ranged from 68% to 91% [69, 70, 71, 72, 73, 74, 75]. Rompe et al reported good or excellent outcome in 48% and an acceptable results in 42% at the final review at 24 weeks in 50 patients with chronic tennis elbow treated with 3,000 impulses of shockwave therapy compared with 6% and 24%, respectively, in the control patients treated with 30 impulses [76]. Wang et al compared the results of shockwave therapy in 57 patients (58 elbows) with lateral epicondylitis of the elbow with a control group of 6 patients (6 elbows) with a follow-up of 12 to 26 months. The overall results of the treatment group were complaints free in 27 (61.4)%, significantly better in 13 (29.5)%, slightly better in 3 (6.8%) and unchanged in 1 (2.3%). Recurrent pain of lesser intensity was noted in 3 patients (6.8%). In the control group, however, the results were unchanged in all 6 patients [77]. Few studies reported no effect of ESWT or less effect comparable to the placebo [78, 79, 80, 81, 82, 83]. In a review of 9 placebo-controlled trials, Buchbinder et al concluded that there is "platinum" level that ESWT provides little or no benefit in term of pain and function in lateral elbow pain. There is "silver" level evidence that steroid injection may be more effective than ESWT [7, 78]. Haake et al in a review of 20 studies concluded that no clinically relevant efficacy has been proven for the use of ESWT for lateral elbow pain [79, 80]. Speed et al in a double blind randomized trial concluded that there appears to be a significant placebo effect of moderate dose of ESWT in subjects with lateral epicondylitis, but there is no evidence of added benefit of treatment when compared to sham therapy [82]. The differences were attributed to the patient selection, the techniques, the manufacture devices, the use of local anesthesia and the method of outcome measurements.

## Calcifying tendinitis of the shoulder

The success rate of shockwave therapy in patients with calcific tendinitis of the shoulder was reported ranging from 78% to 91% [84, 85, 86, 87, 88, 89, 90, 91, 92, 93]. Spindler et al reported complete pain relief and full shoulder joint movement in three patients two years after shockwave therapy, and a fragmentation of calcification was achieved after 24 h [12]. Wang et al compared the results of shockwave therapy in 37 patients (39 shoulders) with calcific tendonitis of the shoulder with a control group of 6 patients (6 shoulders). At 2- to 3-year follow-up, the overall results of the shockwave group were complaints free in 60.6%, significantly better in 30.3%, slightly better in 3.0% and unchanged in 6.1%. Only two patients (6%) showed recurrent pain of lesser intensity, and none showed worse symptoms. The results of the control group were slightly better in 1 (16.7%) and unchanged in 5 (83.3%). Radiographs showed complete elimination of

calcium deposits in 57.6%, partial elimination or fragmentation in 15.1%, and unchanged in 27.3% for the shockwave group. For the control group, the calcium deposit was fragmented in 1 (16.7%) and unchanged in 5 (83.3%). None showed recurrence of calcium deposit 2 years after shockwave therapy. There was a correlation of functional improvement with the elimination of calcium deposit [94]. Jurgowski and Loew treated patients with two sessions of 2,000 impulses each of shockwave and reported a marked reduction of symptoms with an average of 30% improvement in the Constant score at the 12-week follow-up. Radiographs showed complete elimination of the calcification in seven patients, and partial elimination in five patients. Magnetic resonance imaging did not show any lasting damage to bone or soft tissue [95, 96]. Rompe et al reported significant improvement in 72.5% of the patients and only six (15%) of 40 patients treated with 1,500 impulses of shockwaves reported no improvement. Complete or partial disintegration of the calcium deposits was observed in 62.5% of the patients [74]. In another study, Rompe et al reported that shockwave therapy provides equal or better results than surgery in patients with calcifying tendonitis of the shoulder [97].

## Patellar tendinopathy (Jumper's knee) and Achilles tendinopathy

Several studies have reported favorable results of shockwave therapy in athletes with Jumper's knee (patellar tendinopathy) with the success rate ranged from 73.5% to 87.5% [16, 19, 43, 98, 99, 100]. ESWT was also utilized in patients with patellar tendinopathy secondary to harvesting of the patellar tendon for ACL reconstruction. Wang et al compared 30 knees in 27 patients treated with ESWT with 24 knees in 23 patients treated conservatively, the results at 2- to 3-year follow-up showed 43% excellent, 47% good, 10% fair and none poor for the study group, and none excellent, 50% good, 25% fair and 25% poor for the control group ( $P < 0.05$ ). Ultrasonographic examination showed a significant increase in the vascularity of the patellar tendon and a trend of reduction in the patellar tendon thickness after ESWT as compared to conservative treatments [43]. Peers KH et al compared 13 knees treated surgically with 15 knees received ESWT, and reported a comparable functional outcome in patient with patellar tendinopathy resistant to conservative treatments [100]. It appears that ESWT is effective in the management of patients with chronic patellar tendinopathy.

Many studies investigated the effect of ESWT in Achilles tendinopathy, and most reported favorable results with similar success rate as patellar tendinopathy [17, 18, 101, 102, 103]. Rompe et al compared 25 patients treated by eccentric stretching exercises with 25 patients treated with repetitive ESWT, and the results showed that eccentric loading is inferior to ESWT in the treatment of patients with chronic recalcitrant Achilles tendinopathy [101].

## ESWT in bone disorders

### *Non-union and delayed union of long bone fracture*

Several studies investigated the effect of shockwave therapy for non-union and delayed union of long bone fractures, and reported the success rate of achieving bony union ranged from 50% to 85% [13, 14, 104, 105, 106, 107, 108, 109, 110]. Schaden et al reported a success of 85% in the treatment of 115 delayed and non-unions [106]. Valchanou et al [107] reported bony unions in 70 of 82 patients with delayed or chronic nonunion of



fractures at various locations. Vogel et al reported a 60.4% union rate in 48 patients with pseudarthroses treated with 3,000 shockwave impulses [108]. Wang et al treated 72 patients with non-unions of long bone fracture with shockwave therapy, and reported a success rate of 82.4% bony union at 6-month follow-up [104]. Rompe et al reported a 50% success rate in the treatment of delayed bone union with shockwaves in clinical study [109], whereas Schleberger and Senge [110] showed successful fracture healing in three of four pseudoarthroses treated with 2000 impulses of shockwaves. Recently, Elster EA et al reported an 80.2% success in 172 non-union of the tibia [14]. The results of ESWT in non-union of long bone appear to be comparable to surgical intervention. However, the advantages of ESWT include no surgery with no surgical pain and surgical risks.

### *AVNFB (Avascular necrosis of the femoral head)*

For symptomatic hips affected by AVNFB, conservative treatments are generally not successful, and surgery is indicated with the type of surgery varying according to the stage of the disease [111]. Core decompression with or without bone grafting is considered the gold standard of femoral head preserving procedures. However, the results of core decompression varied widely and most reports are unsatisfactory [112]. ESWT was recently utilized in the treatment of early AVNFB. Several articles reported the positive effect of shockwave therapy for AVNFB [21, 22, 113, 114, 115, 116]. Wang et al compared 23 patients with 29 hips treated with ESWT and 25 patients with 28 hips treated by core decompression with non-vascularized fibular bone grafting, total hip arthroplasty (THA) was performed in 3% and 21% ( $P = 0.039$ ) in 1 year, 10% and 32% ( $P = 0.044$ ) in 2 years and 24% and 64% ( $P = 0.002$ ) in 8 to 9-year follow-up for the ESWT group and the surgical group respectively. Significant improvements in pain and function were noted at each time intervals favoring the ESWT. There was a trend of decrease in the size of the lesion in the ESWT group [22, 117]. In animal experiment in rabbits, ESWT was shown to increase BMP-2 protein and mRNA, and up-regulation of VEGF expression in necrotic subchondral bone of the femoral head. The up-regulation of VEGF may play a role inducing the ingrowth of neovascularization and improvement in blood supply to the femoral head [118, 119]. These findings are in concert with our findings with histopathological examination and immunohistochemical analysis, ESWT was shown to promote angiogenesis and bone remodeling and regenerative effect in AVNFB [117]. It appears that ESWT is effective in the retardation or prevention of collapse of the femoral head in early AVNFB. The application of ESWT was also found effective in the treatment of corticosteroid induced AVNFB in patients with systemic lupus erythematosus [114]. Wang et al compared 15 patients with 26 hips in patients with systemic lupus erythematosus with the control of 24 patients with 29 hips, THA was performed in 12% and 14% respectively, and there were no difference in pain and function. It is concluded that the response of patients with SLE to ESWT for AVNFB is comparable to AVNFB in non-SLE patients [114].

### *Other disorders*

Several studies reported a positive effect of shockwave therapy in Peyronie's disease and complex regional pain syndrome (RSD or reflex sympathetic dystrophy) [120], osteoarthritis of the knee [121], spine fusion [122], malignant cells [123, 124], and gene therapy [125]. Furthermore, the application of ESWT has been expanded to

non-musculoskeletal diseases. Recent studies showed that ESWT is effective in chronic diabetic foot ulcers [126, 127] and ischemic heart disease [128, 129].

In conclusion, ESWT is a new non-invasive therapeutic modality with effectiveness, convenience and safety. ESWT has the potential of replacing surgery in many orthopedic disorders without the surgical risks. The complication rates are low and negligible. The exact mechanism of shockwave therapy remains unknown. In animal experiments, ESWT induces a cascade of biological responses and molecular changes including the ingrowth of neo-vascularization and up-regulation of angiogenetic growth factors leading to the improvement in blood supply and tissue regeneration. There is a great potential for translational research and development in the armamentarium of extracorporeal shockwave technology.

## Declarations

### Competing interests

The author declared that he did not receive any honoraria or consultancy fee in writing this manuscript. No benefit was received or will be received directly or indirectly from a commercial party related to the performance of this study. The author has served as the member of scientific advisory committee of Sanuwave (Alpharetta, GA).

### Authors' contributions

C-JW participated in the study with the responsibility in protocol drafting, reference search, data collection and data analysis, manuscript writing and final proof of the manuscript.

## References

1. Buch M, Knorr U, Fleming L, Theodore G, Amendola A, Bachmann C, Zingas C, Siebert WE: Extracorporeal shockwave therapy in symptomatic heel spurs. An overview. *Orthopade*. 2002, 31 (7): 637-44. 10.1007/s00132-002-0323-z.
2. Perez M, Weiner R, Gilley JC: Extracorporeal shock wave therapy for plantar fasciitis. *Clin Podi Med Surg*. 2003, 20 (2): 323-34. 10.1016/S0891-8422(03)00002-8.
3. Roehrig GJ, Baumhauer J, DiGiovanni BF, Flemister AS: The role of extracorporeal shock wave on plantar fasciitis. *Foot Ankle Clin*. 2005, 10 (4): 699-712. 10.1016/j.fcl.2005.06.002.
4. Strash WW, Perez RR: Extracorporeal shockwave therapy for chronic proximal plantar fasciitis. *Clin Podi Med Surg*. 2002, 19 (4): 467-76. 10.1016/S0891-8422(02)00016-2.
5. Thomson CE, Crawford F, Murray GD: The effectiveness of extra corporeal shock wave therapy for plantar heel pain: a systematic review and meta-analysis. *BMC Musculoskelet Disord*. 2005, 6: 19-10.1186/1471-2474-6-19.
6. Wilner JM, Strash WW: Extracorporeal shockwave therapy for plantar fasciitis and other musculoskeletal conditions utilizing the Ossatron-an update. *Clin Podi Med Surg*. 2004, 21 (3): 441-7. j.cpm.2004.03.002.
7. Buchbinder R, Green SE, Youd JM, Assendelft WJ, Barnsley L, Smidt N: Systematic review of the efficacy and safety of shock wave therapy for lateral elbow pain. *J Rheum*. 2006, 33 (7): 1351-63.
8. Rompe JD, Theis C, Maffulli N: Shock wave treatment for tennis elbow. *Orthopade*. 2005, 34 (6): 567-70. 10.1007/s00132-005-0805-x.
9. Rompe JD, Maffulli N: Repetitive shock wave therapy for lateral elbow tendinopathy (tennis elbow): a systematic and qualitative analysis. *Br Med Bulletin*. 2007, 83: 355-78. 10.1093/bmb/ldm019.
10. Stasinopoulos D, Johnson MI: Effectiveness of extracorporeal shock wave therapy for tennis elbow (lateral epicondylitis). *Br J Sports Med*. 2005, 39 (3): 132-6. 10.1136/bjism.2004.015545.
11. Mouzopoulos G, Stamatakis M, Mouzopoulos D, Tzurbakis M: Extracorporeal shock wave treatment for shoulder calcific tendonitis: a systematic review. *SSkeletal Radiol*. 2007, 36 (9): 803-11. 10.1007/s00256-007-0297-3.

12. Spindler A, Berman A, Lucero E, Braier M: Extracorporeal shock wave treatment for chronic calcific tendinitis of the shoulder. *J Rheum.* 1998, 25 (6): 1161-3.
13. Cacchio A, Giordano L, Colafarina O, Rompe JD, Tavernese E, Ioppolo F, Flamini S, Spacca G, Santilli V: Extracorporeal shock-wave therapy compared with surgery for hypertrophic long-bone nonunions. *J Bone Joint Surg -Am.* 2009, 91 (11): 2589-97. 10.2106/JBJS.H.00841. [Erratum appears in *J Bone Joint Surg Am.* 2010 May;92(5):1241]
14. Elster EA, Stojadinovic A, Forsberg J, Shawen S, Andersen RC, Schaden W: Extracorporeal shock wave therapy for nonunion of the tibia. *J Orthop Trauma.* 2010, 24 (3): 133-41. 10.1097/BOT.0b013e3181b26470.
15. Xu ZH, Jiang Q, Chen DY, Xiong J, Shi DQ, Yuan T, Zhu XL: Extracorporeal shock wave treatment in nonunions of long bone fractures. *Int Orthop.* 2009, 33 (3): 789-93. 10.1007/s00264-008-0553-8.
16. van Leeuwen MT, Zwerver J, van den Akker-Scheek I: Extracorporeal shockwave therapy for patellar tendinopathy: a review of the literature. *Br J Sports Med.* 2009, 43 (3): 163-8.
17. Rasmussen S, Christensen M, Mathiesen I, Simonson O: Shockwave therapy for chronic Achilles tendinopathy: a double-blind, randomized clinical trial of efficacy. *Acta Orthop.* 2008, 79 (2): 249-56. 10.1080/17453670710015058.
18. Furia JP: High-energy extracorporeal shock wave therapy as a treatment for chronic noninsertional Achilles tendinopathy. *Am J Sports Med.* 2008, 36 (3): 502-8.
19. Vulpiani MC, Vetrano M, Savoia V, Di Pangrazio E, Trischitta D, Ferretti A: Jumper's knee treatment with extracorporeal shock wave therapy: a long-term follow-up observational study. *J Sports Med Physical Fitness.* 2007, 47 (3): 323-8.
20. Alves EM, Angrisani AT, Santiago MB: The use of extracorporeal shock waves in the treatment of osteonecrosis of the femoral head: a systematic review. *Clin Rheuma.* 2009, 28 (11): 1247-51. 10.1007/s10067-009-1231-y.
21. Kong FR, Liang YJ, Oin SG, Li JJ, Li XL: Clinical application of extracorporeal shock wave to repair and reconstruct osseous tissue framework in the treatment of avascular necrosis of the femoral head (ANFH). *Zhongguo Gushang.* 2010, 23 (1): 12-5.
22. Wang CJ, Wang FS, Huang CC, Yang KD, Weng LH, Huang HY: Treatment for osteonecrosis of the femoral head: comparison of extracorporeal shock waves with core decompression and bone-grafting. *J Bone Joint Surg - Am.* 2005, 87 (11): 2380-7. 10.2106/JBJS.E.00174.
23. Ogden JA, Alvarez RG, Levitt R, Marlow M: Shock wave therapy (lithotripsy) in musculoskeletal disorders. *Clin Orthop.* 2001, 387: 22-40.
24. Buchbinder R, Ptasznik R, Gordon J, Buchanan J, Prabakaran V, Forbes A: Ultrasound-guided extracorporeal shock wave therapy for plantar fasciitis: a randomized controlled trial. *JAMA.* 2002, 288 (11): 1364-72. 10.1001/jama.288.11.1364.
25. Speed CA, Nichols D, Wies J, Humphreys H, Richards C, Burnet S, Hazieman BL: Extracorporeal shock wave therapy for plantar fasciitis. A double blind randomized controlled trial. *J Orthop Res.* 2003, 21 (5): 937-40. 10.1016/S0736-0266(03)00048-2.
26. Ogden JA, Tóth-Kischkat A, Schultheiss R: Principles of shock wave therapy. *Clin Orthop.* 2001, 387: 8-17.
27. Extracorporeal shock waves in orthopaedics. Edited by: Siebert W, Buch M. 1997, Berlin, Springer Verlag, 1-245.
28. Suhr D, Brummer F, Hulser DF: Cavitation-generated free radicals during shock wave exposure investigations with cell-free solutions and suspended cells. *Ultrasound Med boil.* 1992, 17: 761-8.
29. Tomita Y, Shima A: Mechanisms of impulsive pressure generation and damage pit formation by bubble collapse. *J Fluid Mech.* 1986, 169: 535-64. 10.1017/S0022112086000745.
30. Zhong P, Cioanta I, Zhu S, Cocks FH, Preminger GM: Effects of tissue constraint in shock wave-induced bubble expansion in vivo. *J Acoust Soc Am.* 1998, 104: 3126-9. 10.1121/1.423905.
31. Haupt G, Haupt A, Ekkernkamp A, Gerety B, Chvapil M: Influence of shockwave on fracture healing. *J Urol.* 1992, 39: 529-32. 10.1016/0090-4295(92)90009-L.
32. Johannes EJ, Kaulesar Sukul DM, Matura E: High-energy shockwave for treatment of nonunion. An experiment on dogs. *J Surg Res.* 1994, 57: 246-52. 10.1006/jsre.1994.1139.
33. Wang CJ, Huang HY, Chen HH, Pai CH, Yang KD: The effect of shock wave therapy on acute fractures of the tibia. A study in a dog model. *Clin Orthop.* 2001, 387: 112-8.
34. Forriol F, Solchaga L, Moreno JL, Candell J: The effect of shockwave on mature and healing cortical bone. *Int Orthop.* 1994, 8: 325-9.

35. Wang CJ, Yang KD, Wang FS, Hsu CC, Chen HH: Shock wave treatment shows dose-dependent enhancement of bone mass and bone strength after fracture of the femur. *Bone*. 2004, 34: 225-230. 10.1016/j.bone.2003.08.005.
36. Wang FS, Wang CJ, Sheen-Chen SM, Kuo YR, Chen RF, Yang KD: Superoxide mediates shock wave induction of ERK-dependent osteogenic transcription factor (CBFA1) and mesenchymal cell differentiation toward osteoprogenitors. *J Biol Chem*. 2002, 277 (13): 10931-7. 10.1074/jbc.M104587200.
37. Wang FS, Yang KD, Chen RF, Wang CJ, Sheen-Chen SM: Extracorporeal shock wave promotes growth and differentiation of bone-marrow stromal cells towards osteoprogenitors associated with induction of TGF-beta1. *J Bone Joint Surg Br*. 2002, 84 (3): 457-61. 10.1302/0301-620X.84B3.11609.
38. Wang FS, Wang CJ, Huang HC, Chung H, Chen RF, Yang KD: Physical shock wave mediates membrane hyperpolarization and Ras activation for osteogenesis in human bone marrow stromal cells. *Biochem Biophys Res Commun*. 2001, 287: 648-55. 10.1006/bbrc.2001.5654.
39. Chen YJ, Wurtz T, Wang CJ, Kuo RY, Yang KD, Huang HC, Wang FS: Recruitment of mesenchymal stem cells and expression of TGF-beta 1 and VEGF in the early stage of shock wave-promoted bone regeneration of segmental defect in rats. *J Orthop Res*. 2004, 22 (3): 526-34. 10.1016/j.jorthres.2003.10.005.
40. Rompe JD, Kirkpatrick CJ, Kullmer K, Schwitalle M, Krischek O: Dose-related effects of shock waves on rabbit tendo Achillis. *J Bone Joint Surg Br*. 1998, 80B: 546-52.
41. Wang CJ, Huang HY, Pai CH: Shock wave enhances neovascularization at the tendon-bone junction. *J Foot Ankle Surg*. 2002, 41 (1): 16-22. 10.1016/S1067-2516(02)80005-9.
42. Wang CJ, Yang KD, Wang FS, Huang CC, Yang LJ: Shock wave induces neovascularization at the tendon-bone junction. A study in rabbits. *J Orthop Res*. 2003, 21: 984-989. 10.1016/S0736-0266(03)00104-9.
43. Wang CJ, Ko JY, Chan YS, Weng LH, Hsu SL: Extracorporeal shockwave for chronic patellar tendinopathy. *Am J Sports Med*. 2007, 35 (6): 972-8. 10.1177/0363546506298109.
44. Lian O, Dahl J, Ackermann PW, Frihagen F, Engebretsen L, Bahr R: Pronociceptive and antinociceptive neuromediators in patellar tendinopathy. *Am J Sports Med*. 2006, 34 (11): 1801-8. 10.1177/0363546506289169.
45. Chen HS, Chen LM, Huang TW: Treatment of painful heel syndrome with shock waves. *Clin Orthop*. 2001, 387: 41-6.
46. Chuckpaiwong B, Berkson EM, Theodore GH: Extracorporeal shock wave for chronic proximal plantar fasciitis: 225 patients with results and outcome predictors. *J Foot Ankle Surg*. 2009, 48 (2): 148-55. 10.1053/j.jfas.2008.11.001.
47. Gerdesmeyer L, Frey C, Vester J, Maier M, Weil L, Weil L, Russlies M, Stienstra J, Scurran B, Fedder K, Diehl P, Lohrer H, Henne M, Gollwitzer H: Radial extracorporeal shock wave therapy is safe and effective in the treatment of chronic recalcitrant plantar fasciitis: results of a confirmatory randomized placebo-controlled multicenter study. *Am J Sports Med*. 2008, 36 (11): 2100-9. 10.1177/0363546508324176.
48. Gollwitzer H, Diehl P, von Korff A, Rahlfs VW, Gerdesmeyer L: Extracorporeal shock wave therapy for chronic painful heel syndrome: a prospective, double blind, randomized trial assessing the efficacy of a new electromagnetic shock wave device. *J Foot Ankle Surg*. 2007, 46 (5): 348-57. 10.1053/j.jfas.2007.05.011.
49. Hammer DS, Adam F, Kreutz A, Kohn D, Seil R: Extracorporeal shock wave therapy (ESWT) in patients with chronic proximal plantar fasciitis: a 2-year follow-up. *Foot Ankle Int*. 2003, 24 (11): 823-8.
50. Hyer CF, Vancourt R, Block A: Evaluation of ultrasound-guided extracorporeal shock wave therapy (ESWT) in the treatment of chronic plantar fasciitis. *J Foot Ankle Surg*. 2005, 44 (2): 137-43. 10.1053/j.jfas.2005.01.005.
51. Ibrahim MI, Donatelli RA, Schmitz C, Hellman MA, Buxbaum F: Chronic plantar fasciitis treated with two sessions of radial extracorporeal shock wave therapy. *Foot Ankle Int*. 2010, 31 (5): 391-7. 10.3113/FAI.2010.0391.
52. Kudo P, Dainty K, Clarfield M, Coughlin L, Lavoie P, Lebrun C: Randomized, placebo-controlled, double-blind clinical trial evaluating the treatment of plantar fasciitis with an extracorporeal shockwave therapy (ESWT) device: a North American confirmatory study. *J Orthop Res*. 2006, 24 (2): 115-23. 10.1002/jor.20008.
53. Metzner G, Dohnalek C, Aigner E: High-energy Extracorporeal Shock-Wave Therapy (ESWT) for the treatment of chronic plantar fasciitis. *Foot Ankle Int*. 2010, 31 (9): 790-6. 10.3113/FAI.2010.0790.

54. Norris DM, Eickmeier KM, Werber BR: Effectiveness of extracorporeal shockwave treatment in 353 patients with chronic plantar fasciitis. *J Am Podi Med Asso.* 2005, 95 (6): 517-24.
55. Ogden JA, Alvarez RG, Levitt RL, Johnson JE, Marlow ME: Electrohydraulic high-energy shock-wave treatment for chronic plantar fasciitis. *J Bone Joint Surg - Am.* 2004, 86 (10): 2216-28.
56. Rajkumar P, Schmitgen GF: Shock waves do more than just crush stones: extracorporeal shock wave therapy in plantar fasciitis. *Int J Clin Pract.* 2002, 56 (10): 735-7.
57. Rompe JD, Decking J, Schoellner C, Nafe B: Shock wave application for chronic plantar fasciitis in running athletes. A prospective, randomized, placebo-controlled trial. *Am J Sports Med.* 2003, 31 (2): 268-75.
58. Rompe JD, Schoellner C, Nafe B: Evaluation of low-energy extracorporeal shock-wave application for treatment of chronic plantar fasciitis. *J Bone Joint Surg- Am.* 2002, 84 (3): 335-41. 10.1302/0301-620X.84B3.12460.
59. Wang CJ, Chen HS, Chen WS, Chen LM: Treatment of painful heels using extracorporeal shock wave. *J Formosan Med Asso.* 2000, 99 (7): 580-3.
60. Wang CJ, Chen HS, Huang TW: Shockwave therapy for patients with plantar fasciitis: a one-year follow-up study. *Foot Ankle Int.* 2002, 23 (3): 204-7.
61. Wang CJ, Wang FS, Yang KD, Weng LH, Ko JY: Long-term results of extracorporeal shockwave treatment for plantar fasciitis. *Am J Sports Med.* 2006, 34 (4): 592-6. 10.1177/0363546505281811.
62. Weil LS, Roukis TS, Weil LS, Borrelli AH: Extracorporeal shock wave therapy for the treatment of chronic plantar fasciitis: indications, protocol, intermediate results, and a comparison of results to fasciotomy. *J Foot Ankle Surg.* 2002, 41 (3): 166-72. 10.1016/S1067-2516(02)80066-7.
63. Greve JM, Grecco MV, Santos-Silva PR: Comparison of radial shockwaves and conventional physiotherapy for treating plantar fasciitis. *Clinics (Sao Paulo, Brazil).* 2009, 64 (2): 97-103. 10.1590/S1807-59322009000200006.
64. Haake M, Buch M, Schoellner C, Goebel F, Vogel M, Mueller I, Hausdorf J, Zamzow K, Schade-Brittinger C, Mueller HH: Extracorporeal shock wave therapy for plantar fasciitis: randomised controlled multicentre trial. *BMJ.* 2003, 327 (7406): 75-10.1136/bmj.327.7406.75.
65. Othman AM, Ragab EM: Endoscopic plantar fasciotomy versus extracorporeal shock wave therapy for treatment of chronic plantar fasciitis. *Arch Orthop Trauma Surg.* 2010, 130 (11): 1343-7. 10.1007/s00402-009-1034-2.
66. Yucel I, Ozturan KE, Demiraran Y, Degirmenci E, Kaynak G: Comparison of high-dose extracorporeal shockwave therapy and intralesional corticosteroid injection in the treatment of plantar fasciitis. *J Am Podi Med Asso.* 2010, 100 (2): 105-10.
67. Labek G, Auersperg V, Ziernhold M, Poullos N, Bohler N: Influence of local anesthesia and energy level on the clinical outcome of extracorporeal shock wave-treatment of chronic plantar fasciitis. *Zeitschrift fur Orthopadie und Ihre Grenzgebiete.* 2005, 143 (2): 240-6. 10.1055/s-2004-832379.
68. Rompe JD, Meurer A, Nafe B, Hofmann A, Gerdsmeyer L: Repetitive low-energy shock wave application without local anesthesia is more efficient than repetitive low-energy shock wave application with local anesthesia in the treatment of chronic plantar fasciitis. *J Ortho Res.* 2005, 23 (4): 931-41.
69. Furia JP: Safety and efficacy of extracorporeal shock wave therapy for chronic lateral epicondylitis. *Am J Orthop (Chatham, NJ).* 2005, 34 (1): 13-9. discussion 19, 2005 Jan
70. Ko JY, Chen HS, Chen LM: Treatment of lateral epicondylitis of the elbow with shock waves. *Clin Orthop.* 2001, 387: 60-7.
71. Ozturan KE, Yucel I, Cakici H, Guven M, Sungur I: Autologous blood and corticosteroid injection and extracorporeal shock wave therapy in the treatment of lateral epicondylitis. *Orthopedics.* 2010, 33 (2): 84-91. 10.3928/01477447-20100104-09.
72. Radwan YA, ElSobhi G, Badawy WS, Reda A, Khalid S: Resistant tennis elbow: shock-wave therapy versus percutaneous tenotomy. *Int Orthop.* 2008, 32 (5): 671-7. 10.1007/s00264-007-0379-9.
73. Rompe JD, Decking J, Schoellner C, Theis C: Repetitive low-energy shock wave treatment for chronic lateral epicondylitis in tennis players. *Am J Sports Med.* 2004, 32 (3): 734-43. 10.1177/0363546503261697.
74. Rompe JD, Eysel P, Hopf C, Krischek O, Vogel J, Burger R, Jage J, Heine J: [Extracorporeal shockwave therapy in orthopedics. Positive results in tennis elbow and tendinosis calcarea of the shoulder]. *Fortschritte der Medizin.* 1997, 26 (18): 29-33.
75. Spacca G, Necozone S, Cacchio A: Radial shock wave therapy for lateral epicondylitis: a prospective randomised controlled single-blind study. *Europa Medicophysica.* 2005, 41 (1): 17-25.

76. Rompe JD, Hope C, Kullmer K, Heine J, Burger R: Analgesic effect of extracorporeal shock-wave therapy on chronic tennis elbow. *J Bone Joint Surg Br.* 1996, 78 (2): 233-7.
77. Wang CJ, Chen HS: Shock wave therapy for patients with lateral epicondylitis of the elbow: a one-to-two-year follow-up study. *Am J Sports Med.* 2002, 30 (3): 422-5.
78. Buchbinder R, Green SE, Youd JM, Assendelft WJ, Barnsley L, Smidt N: Shock wave therapy for lateral elbow pain. *Cochrane Database of Systematic Reviews.* 2005, CD003524-[Update of Cochrane Database Syst Rev. 2002, (1):CD003524; PMID: 11869669] Reviews, 4
79. Haake M, Hunerkopf M, Gerdesmeyer L, Konig IR: Extracorporeal shockwave therapy (ESWT) in epicondylitis humeri radialis. A review of the literature. *Orthopade.* 2002, 31 (7): 623-32. 10.1007/s00132-002-0321-1.
80. Haake M, Konig IR, Decker T, Riedel C, Buch M, Muller HH: Extracorporeal shock wave therapy in the treatment of lateral epicondylitis: a randomized multicenter trial. Extracorporeal Shock Wave Therapy Clinical Trial Group. *J Bone Joint Surg - Am.* 2002, 84 (11): 1982-91.
81. Melikyan EY, Shahin E, Miles J, Bainbridge LC: Extracorporeal shock-wave treatment for tennis elbow. A randomised double-blind study. *J Bone Joint Surg Br.* 2003, 85 (6): 852-5.
82. Speed CA, Nichols D, Richards C, Humphreys H, Wies JT, Burnet S, Hazleman BL: Extracorporeal shock wave therapy for lateral epicondylitis-a double blind randomised controlled trial. *J Orthop Res.* 2002, 22 (5): 895-898.
83. Staples MP, Forbes A, Ptasznik R, Gordon J, Buchbinder R: A randomized controlled trial of extracorporeal shock wave therapy for lateral epicondylitis (tennis elbow). *J Rheuma.* 2008, 35 (10): 2038-46.
84. Cacchio A, Paoloni M, Barile A, Don R, de Paulis F, Calvisi V, Ranavolo A, Frascarelli M, Santilli V, Spacca G: Effectiveness of radial shock-wave therapy for calcific tendinitis of the shoulder: single-blind, randomized clinical study. *Phys Ther.* 2006, 86 (5): 672-82.
85. Daecke W, Kusnierczak D, Loew M: Long-term effects of extracorporeal shockwave therapy in chronic calcific tendinitis of the shoulder. *J Shoulder Elbow Surg.* 2002, 11 (5): 476-80. 10.1067/mse.2002.126614.
86. Hsu CJ, Wang DY, Tseng KF, Fong YC, Hsu HC, Jim YF: Extracorporeal shock wave therapy for calcifying tendinitis of the shoulder. *J Shoulder Elbow Surg.* 2008, 17 (1): 55-9. 10.1016/j.jse.2007.03.023.
87. Jakobeit C, Winiarski B, Jakobeit S, Welp L, Spelsberg G: Ultrasound-guided, high-energy extracorporeal shock-wave treatment of symptomatic calcareous tendinopathy of the shoulder. *ANZ J Surg.* 2002, 72 (7): 496-500. 10.1046/j.1445-2197.2002.02423.x.
88. Krasny C, Enenkel M, Aigner N, Wik M, Landsiedl F: Ultrasound-guided needling combined with shock-wave therapy for the treatment of calcifying tendonitis of the shoulder. *J Bone Joint Surg Br.* 2005, 87 (4): 501-7. 10.1302/0301-620X.87B4.15769.
89. Pan PJ, Chou CL, Chiou HJ, Ma HL, Lee HC, Chan RC: Extracorporeal shock wave therapy for chronic calcific tendinitis of the shoulders: a functional and sonographic study. *Arch Phy Med Rehab.* 2003, 84 (7): 988-93. 10.1016/S0003-9993(03)00010-8.
90. Peters J, Luboldt W, Schwarz W, Jacobi V, Herzog C, Vogl TJ: Extracorporeal shock wave therapy in calcific tendinitis of the shoulder. *Skeletal Radiol.* 2004, 33 (12): 712-8. 10.1007/s00256-004-0849-8.
91. Pleiner J, Crevenna R, Langenberger H, Keilani M, Nuhr M, Kainberger F, Wolzt M, Wiesinger G, Quittan M: Extracorporeal shockwave treatment is effective in calcific tendonitis of the shoulder. A randomized controlled trial. *Wien Klin Wochenschr.* 2004, 116 (15-16): 536-41. 10.1007/BF03217707.
92. Rompe JD, Burger R, Hopf C, Eysel P: Shoulder function after extracorporeal shock wave therapy for calcific tendinitis. *J Shoulder Elbow Surg.* 1998, 7 (5): 505-9. 10.1016/S1058-2746(98)90203-8.
93. Wang CJ, Ko JY, Chen HS: Treatment of calcifying tendinitis of the shoulder with shock wave therapy. *Clin Orthop.* 2001, 387: 83-9.
94. Wang CJ, Yang KD, Wang FS, Chen HH, Wang JW: Shock wave therapy for calcific tendinitis of the shoulder: a prospective clinical study with two-year follow-up. *Am J Sports Med.* 2003, 31 (3): 425-30.
95. Jurgowski W, Loew M, Cotta H, Staehler G: Extracorporeal shock wave treatment of calcareous tendonitis of the shoulder. *J Endourol.* 1993, 7 (Suppl 1): 13-17.
96. Loew M, Daecke W, Kusnierczak D, Rahmanzadeh M, Ewerbeck V: Shock wave application in calcifying tendinitis of the shoulder: prediction of outcome by imaging. *Arch Orthop Trauma Surg.* 2000, 120: 43-8.

98. Zwerver J, Dekker F, Pepping GJ: Patient guided Piezo-electric Extracorporeal Shockwave Therapy as treatment for chronic severe patellar tendinopathy: a pilot study. *J Back Musculoskeletal Rehab.*
99. Hsu RW, Hsu WH, Tai CL, Lee KF: Effect of shock-wave therapy on patellar tendinopathy in a rabbit model. *J Orthop Res.* 2004, 22 (1): 221-7. 10.1016/S0736-0266(03)00138-4.
100. Peers KH, Lysens RJ, Brys P, Bellemans J: Cross-sectional outcome analysis of athletes with chronic patellar tendinopathy treated surgically and by extracorporeal shock wave therapy. *Clin J Sport Med.* 2003, 13 (2): 79-83. 10.1097/00042752-200303000-00003.
101. Rompe JD, Furia J, Maffulli N: Eccentric loading compared with shock wave treatment for chronic insertional achilles tendinopathy. A randomized, controlled trial. *J Bone Joint Surg - Am.* 2008, 90 (1): 52-61. 10.2106/JBJS.F.01494.
102. Furia JP: High-energy extracorporeal shock wave therapy as a treatment for insertional Achilles tendinopathy. *Am J Sports Med.* 2006, 34 (5): 733-40.
103. Furia JP: Extracorporeal shockwave therapy in the treatment of chronic insertional Achilles tendinopathy. *Orthopade.* 2005, 34 (6): 571-8. 10.1007/s00132-005-0806-9.
104. Wang CJ, Chen HS, Chen CE, Yang KD: Treatment of nonunions of long bone fractures with shock waves. *Clin Orthop Rel Res.* 2001, 387: 95-101.
105. Haupt G: Use of extracorporeal shock wave in the treatment of pseudoarthrosis, tendinopathy and other orthopaedic disease. *J Urology.* 1997, 158: 4-11. 10.1097/00005392-199707000-00003.
106. Schaden W, Fischer A, Sailer A: Extracorporeal shock wave therapy of nonunion or delayed osseous union. *Clin Orthop.* 2001, 387: 90-4.
107. Valchanou VD, Michailow P: High-energy shock waves in the treatment of delayed and nonunion of fractures. *Int Orthop.* 1991, 151: 181-4.
108. Vogel J, Hopf C, Eysel P, Rompe JD: Application of extracorporeal shock-waves in the treatment of pseudarthrosis of the lower extremity: preliminary results. *Arch Orthop Trauma Surg.* 1997, 116: 480-3. 10.1007/BF00387581.
109. Rompe JD, Rosendahl T, Schöllner C, Theis C: High-energy extracorporeal shock wave treatment of nonunions. *Clin Orthop.* 2001, 387: 102-111.
110. Schleberger R, Senge T: Noninvasive treatment of long bone pseudoarthrosis by shock waves (ESWL). *Acta Orthop Trauma Surg.* 1992, 111: 224-7. 10.1007/BF00571482.
111. Mont MA, Jones LC, Hungerford DS: Nontraumatic osteonecrosis of the femoral head: ten years later. *J Bone Joint Surg - Am.* 2006, 88 (5): 1117-32. 10.2106/JBJS.E.01041.
112. Mont MA, Carbone JJ, Fairbank AC: Core decompression versus nonoperative management for osteonecrosis of the hip. *Clin Orthop.* 1996, 324: 169-78.
113. Ludwig J, Lauber S, Lauber HJ, Dreisilker U, Raedel R, Hotzinger H: High-energy shock wave treatment of femoral head necrosis in adults. *Clin Orthop.* 2001, 387: 119-26.
114. Lin PC, Wang CJ, Yang KD, Wang FS, Ko JY, Huang CC: Extracorporeal shockwave treatment of osteonecrosis of the femoral head in systemic lupus erythematosus. *J Arthroplasty.* 2006, 21 (6): 911-5. 10.1016/j.arth.2005.11.004.
115. Wang CJ, Ko JY, Chan YS, Lee MS, Chen JM, Wang FS, Yang KD, Huang CC: Extracorporeal shockwave for hip necrosis in systemic lupus erythematosus. *Lupus.* 2009, 18 (12): 1082-6. 10.1177/0961203309103151.
116. Wang CJ, Wang FS, Yang KD, Huang CC, Lee MS, Chan YS, Wang JW, Ko JY: Treatment of osteonecrosis of the hip: comparison of extracorporeal shockwave with shockwave and alendronate. *Arch Orthop Trauma Surg.* 2008, 128 (9): 901-8. 10.1007/s00402-007-0530-5.
117. Wang CJ, Wang FS, Ko JY, Huang HY, Chen CJ, Sun YC, Yang YJ: Extracorporeal shockwave therapy shows regeneration in hip necrosis. *Rheumatology.* 2008, 47 (4): 542-6.
118. Ma HZ, Zeng BF, Li XL, Chai YM: Temporal and spatial expression of BMP-2 in sub-chondral bone of necrotic femoral heads in rabbits by use of extracorporeal shock waves. *Acta Orthopaedica.* 2008, 79 (1): 98-105. 10.1080/17453670710014833.
119. Ma HZ, Zeng BF, Li XL: Upregulation of VEGF in subchondral bone of necrotic femoral heads in rabbits with use of extracorporeal shock waves. *Calcif Tissue Int.* 2007, 81 (2): 124-31. 10.1007/s00223-007-9046-9.
120. Notarnicola A, Moretti L, Tafuri S, Panella A, Filipponi M, Casalino A, Panella M, Moretti B: Shockwave therapy in the management of complex regional pain syndrome in medial femoral condyle of the knee. *Ultrasound Med Biology.* 2010, 36 (6): 874-9. 10.1016/j.ultrasmedbio.2010.03.012.

121. Wang CJ, Ko JY, Weng LH, Wang JW, Chen JM, Sun YC, Yang YJ: Extracorporeal Shockwave Shows Regression of Osteoarthritis of the Knee in Rats. *J Surg Res.* 2011,
122. Lee TC, Yang YL, Chang NK, Lin TS, Lin WC, Liu YS, Wang CJ: Biomechanical testing of spinal fusion segments enhanced by extracorporeal shock wave treatment in rabbits. *Chang Gung Med J.* 2009, 32 (3): 276-82.
123. Brümmer F, Suhr D, Hulser DF: Sensitivity of normal and malignant cells to shock waves. *J Stone Dis.* 1992, 4 (3): 243-8.
124. Russo P, Stephenson RA, Mies C, Huryk R, Heston WD, Melamed MR, Fair WR: High energy shock waves suppress tumor growth in vitro and in vivo. *J Uro.* 1986, 135 (3): 626-8.
125. Lauer U, Burgelt E, Squire Z, Messmer K, Hofschneider PH, Gregor M, Delius M: Shock wave permeabilization as a new gene transfer method. *Gene Therapy.* 1997, 4 (7): 710-5. 10.1038/sj.gt.3300462.
126. Wang CJ, Kuo YR, Wu RW, Liu RT, Hsu CS, Wang FS, Yang KD: Extracorporeal shockwave for diabetic foot ulcers. *J Surg Res.* 2009, 152: 96-103. 10.1016/j.jss.2008.01.026.
127. Kuo YR, Wang CT, Wang FS, Chiang YC, Wang CJ: Extracorporeal shock-wave therapy enhanced wound healing via increasing topical blood perfusion and tissue regeneration in a rat model of STZ-induced diabetes. *Wound Repair Reg.* 2009, 17 (4): 522-30. 10.1111/j.1524-475X.2009.00504.x.
128. Kikuchi Y, Ito K, Ito Y, Shioto T, Tsuburaya R, Aizawa K, Hao K, Fukumoto Y, Takahashi J, Takeda M, Nakayam M, Yasuda S, Kuriyama S, Tsuji I, Shimokawa H: Double-blind and placebo-controlled study of the effectiveness and safety of extracorporeal cardiac shockwave therapy for severe angina pectoris. *Circ J.* 2010, 74 (3): 589-91. 10.1253/circj.CJ-09-1028.
129. Sheu JJ, Sun CK, Chang LT, Fang HY, Chung SY, Chua S, Fu M, Lee FY, Kao YH, Ko SF, Wang CJ, Yen CH, Leu S, Yip HK: Shock wave-pretreated bone marrow cells further improve left ventricular function after myocardial infarction in rabbits. *Ann Vasc Surg.* 2010, 24 (6): 809-821. 10.1016/j.avsg.2010.03.027.

© Wang; licensee BioMed Central Ltd. 2012

This article is published under license to BioMed Central Ltd. This is an Open Access article distributed under the terms of the Creative Commons Attribution License (<http://creativecommons.org/licenses/by/2.0>), which permits unrestricted use, distribution, and reproduction in any medium, provided the original work is properly cited.



In 2017, a European study using CellSonic VIPP on patients with 75 leg ulcers showed the following results:

## Cellular Physiology and Biochemistry

Cell Physiol Biochem 2017;41:890-906

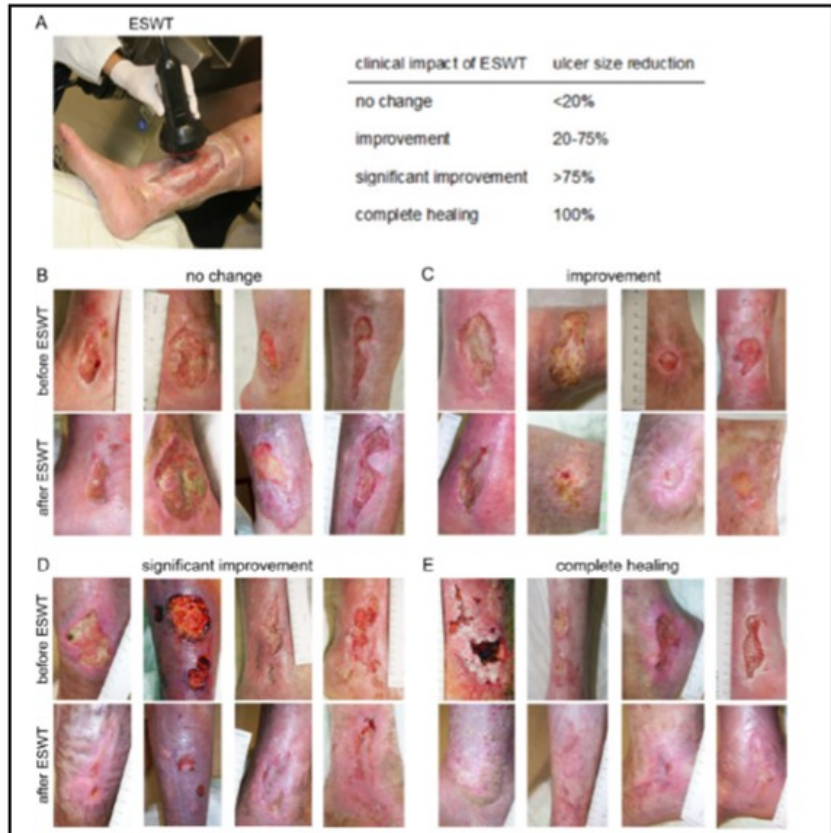
DOI: 10.1159/000460503

Published online: February 20, 2017

© 2017 The Author(s). Published by S. Karger AG, Basel  
www.karger.com/cpb

Aschermann et al.: Impact of Extracorporeal Shock Waves on Wound Healing

**Fig. 5.** Clinical impact of extracorporeal shock wave treatment on chronic leg ulcers. ESWT was performed on therapy-refractory chronic leg ulcers (n=75). Application of ESWT on a leg ulcer using the CellSonic® medical device (A). Exemplary images (n=4) of the four different categories of healing upon ESWT used for statistical evaluation (no change (B), improvement (C), significant improvement (D), and complete healing (E), compare Table 3).



**Table 3.** ESWT treatment response of the 75 treated ulcers.

Outcome	Ulcer pathophysiology		
	Venous (n=43)	Mixed (n=11)	Other (n=21)
Complete healing	49%	18%	38%
Significant improvement	16%	9%	19%
Improvement	28%	64%	33%
No change	7%	9%	10%
Overall ESWT response	93%	91%	90%

(9%), 7 improved (64%), and 1 did not improve (9%). In the third group ("other", n=21), 8 completely healed (38%), 4 significantly improved (19%), 7 improved (33%), and 2 did not improve (10%).



**CellSonic**

[www.cellsonic-medical.com](http://www.cellsonic-medical.com)