


Dr. PURSHOTTAM BAGUL CASE SUMMARY



Name of Patient : Dr. Purshottam Bagul

Age : 40 yrs

Resident of : Malegaon(place @ 300 kms from Pune)

: Dr. Bagul is having a 15 bed ICU multispeciality hospital at Malegaon city.

Problem Diagnosis : Around 5 years back , Dr. Bagul was diagnosed with having H/O DVT right leg and later on developed varicose vein . From around one and a half years, he developed varicose ulcer on left leg. The ulcers used to take months to heal and Dr. Bagul was under immense pain and also his mobility was very restricted. Around one and a half months ago he again developed the varicose ulcer which becoming gangrenous. As per the local consulting surgeon he was advised to undergo I&D for gangrene tissue and plastic surgery. Fortunately for Dr. Bagul , a senior physician from Malegan , Dr. Y.N.Patil advised him to go for a non invasive treatment upon which he contacted Cellsonic India representative Manoj Borade and was first treated on 30th April 2016 which was his first session. (Dr. Y. N. Ptatil had visited the Cellsonic booth at the MEDICA 2016 in Mumbai wherein Cellsonic had showcased its product the VIPP machine).

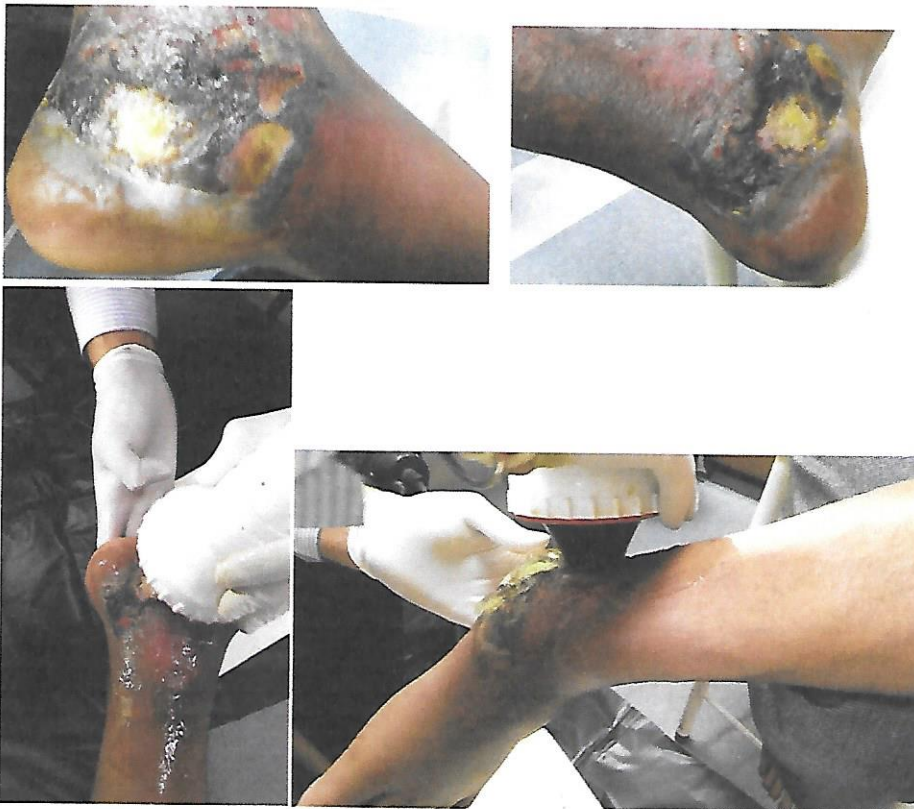Mr. Bagul when arrived at the clinic for the first treatment on 30th April 2016, he was wheeled in in a wheel chair as he was unable to walk because of intense pain. Today as on 27th May 2016 , he walked into the clinic located on the first floor. He did confirm that he still had some pain but it was bearable and did not restrict any of his movements.

Below is a hand written appreciation letter given to Guru Seva Sales(Cellsonic India) where he has himself stated that he has found a tremendous improvement.

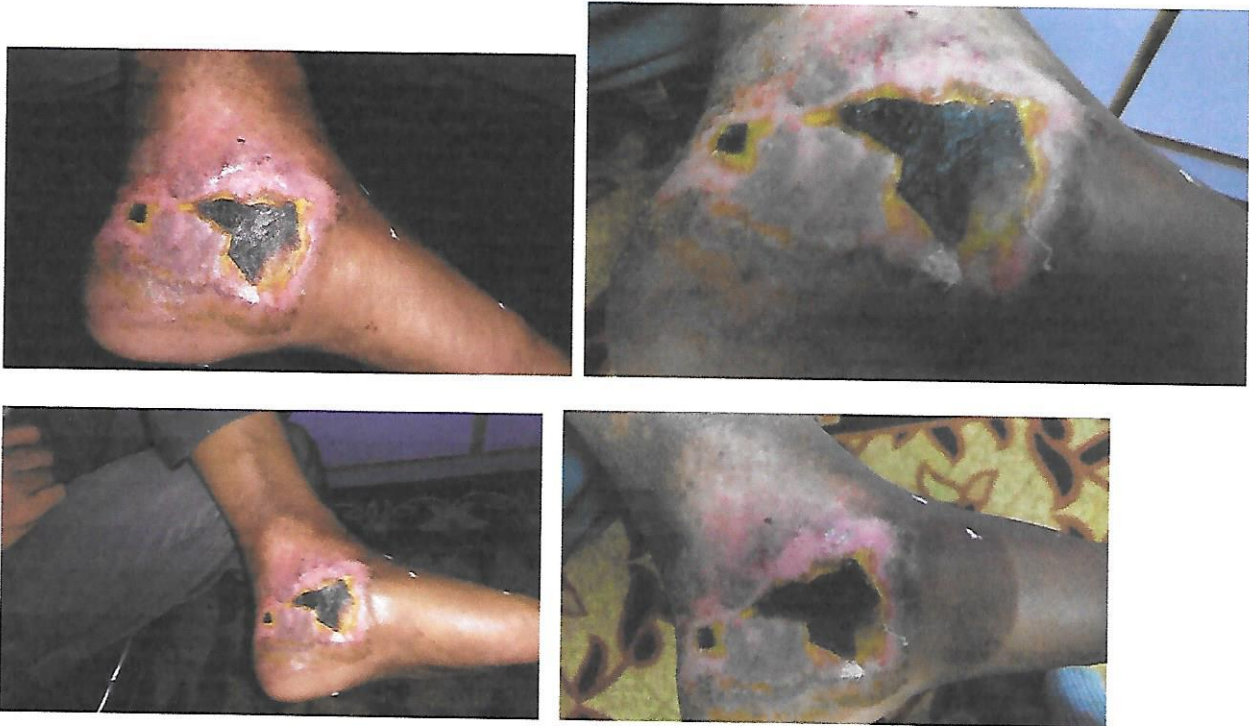Sessoin 1 : 30th April 2016 – treated with 3000 VIPP pulses on the wound and well around the wound upto the knee.

Session 2 : 27th April 2016—treated with 1500 VIPP pulses on the wound and well around it upto knee.

Photographs of ulcer treatment day 1 30th April 2016:



Photographs of ulcer day 2 treatment 27th May 2016



Looking at the speed of improvement in the ulcer healing , it can be said that Dr. Bagul may not require any further VIPP treatment.

Cellsonic VIPP – “ Lowest Cost of Cure” – “ Drug Free”

ZERO side effects.

Letter of Appreciation issued by Dr. Bagul – ref. page 4



संकल्प हॉस्पिटल
अॅन्ड रिसर्च सेंटर प्रा.लि.

संकल्प हॉस्पिटल अॅन्ड रिसर्च सेंटर प्रा.लि.

Jaju Hospital Building, Satana Road, Malegaon. (Nashik) - 423203 Ph.: 02554-250600. e-mail : sankalphosp2013@gmail.com

27/5/2016.

To,
Mr. Mangj Borade.
Guru Serva Services.
Pune.

Sr.
Greetings for the day.
Myself Dr. Purushottam P. Bagul Age 40 yrs R/o
Malegaon. I had H/o DVT (L) leg 5 yrs back, later
on develop varicose vein. Recently since last
1 1/2 yr. I develop leg ulcer to left leg on
lateral malleolus and medial malleolus respectively
since around 1 1/2 month my leg ulcer converted
into gangrenous part. As per advice by surgeon
I required I & D for gangrene tissue &
plastic surgery, But one of Senior physician
from Malegaon Dr. Y.W. Patil. advise me to
non-invasive R/o first. So, I decided to
take Cellsonic treatment On 30/4/2015
my first treatment session done by Mr. Mangj
Sir at pune. Today there is tremendous
improvement in leg ulcer wound. I hope.
fully wants to continue the treatment
Thanking you & regards.
YLL Bagul
Dr. Purushottam Bagul.